

Case Report-IV

Solid Pseudopapillary Tumour of Pancreas – A Case Report.

M. L. GUPTA, ASHISH K OHRI, JASDEEP SINGH, SANJEEV SINGLA ,
DEVINDER SINGH,

ABSTRACT

Solid pseudopapillary tumour is a rare pancreatic tumour which has low malignant potential. It occurs commonly in young females. We report a case of 34 year old female who presented with pain in epigastrium of two years duration with associated bilateral inguinal and axillary lymphadenopathy. Pancreaticoduodenectomy was done as the definitive treatment. The importance of accurate diagnosis and early treatment is emphasized.

INTRODUCTION

Solid pseudopapillary tumor (SPT) of pancreas is a rare pathological condition with very low incidence rate.¹ It has a low malignant potential and commonly affects young females in second or third decade of their lives.² It was first described by Frantz in 1959.³ There has been a recent increase in the number of cases with pseudopapillary tumour of the pancreas and this possibly is because of increased awareness of this entity. Despite increased recognition, it still remains a surgical enigma for most of the

surgeons across the world. Recently we came across a case of solid pseudopapillary tumour of pancreas is very few cases of pseudopapillary tumour of the pancreas have been reported from India.

CASE : 34 year old female presented with pain in the epigastrium of two years duration with radiation to back and occasional vomiting without any history of jaundice or fever. On examination, patient had mild epigastric tenderness. She also had bilateral inguinal lymphadenopathy and left axillary lymphadenopathy. Axillary lymph node biopsy was done which revealed reactive hyperplasia.

Ultrasound of the abdomen showed 50 x 40 x 43 mm complex mass with a central cystic zone between left lobe of the liver and junction of body and tail of the pancreas.

CECT abdomen showed 66 x 50 mm round heterogeneous mass with necrotic zones in the region of the porta hepatis and a volume defect in the head of the pancreas (Fig 1).

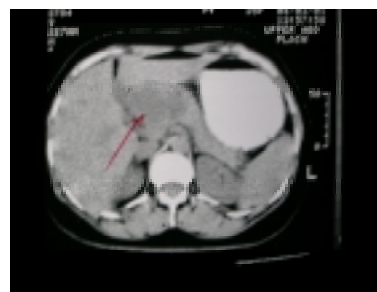


Fig 1: CECT of the abdomen showing heterogeneous mass with necrotic zones in the region of the porta

Diagnostic laparoscopy was done which showed a cystic tumour arising from superior border of the pancreas. In the same stage, the surgical procedure was converted to open laparotomy and after establishing the operability, pancreatoduodenectomy was done. No adjuvant chemotherapy or radiotherapy was given.

The histopathology report was consistent with the solid pseudopapillary tumour of the pancreas with reactive hyperplasia of the regional lymph nodes and tumor free margins. Patient is doing well on three months of follow up.

DISCUSSION

Pancreatic tumors have been categorized as exocrine and endocrine tumors and have been subdivided into solid or cystic epithelial and functional or non functional endocrine tumors. Cystic tumors include serous cystic, mucinous cystic, intraductal papillary mucinous and solid pseudopapillary tumors.

Solid pseudopapillary tumor of pancreas has many synonyms described in the literature as Frantz's tumor, solid cystic tumor of pancreas, papillary cystic neoplasm and solid and cystic acinar cell tumor.

A total of around 450 cases of solid pseudopapillary have been reported in the literature.⁴ More than two third of such patients have been reported in the last decade. They are generally benign as our patient but metastasis to liver has been reported.⁵ The main presenting complaint is the pain abdomen which may be mild to severe but constant in nature.

Our patient had bilateral inguinal and axillary lymphadenopathy. This was the reason that a possibility of lymphoma was considered. The lymphadenopathy were found to be reactive hyperplasia on axillary lymph node biopsy. CT scan showed the mass arising from the head of the pancreas and reaching upto the left lobe of liver. Size of the lesion does not decide the resectability in case of SPT of pancreas with lesions upto 20-30 cm in size have been resected.⁴ Metastasis to liver does not constitute a contraindication to the resection and the tumors

with synchronous metastasis to liver have been resected and have shown good response.⁴ They rarely invade the contiguous structures. Reports have shown resectability and long term survival with isolated portal vein and arterial resection and reconstruction. Recurrence of the tumor after the resection of the metastatic disease has been reported.

Pathological diagnosis of SPT is made on the characteristic light microscopic appearance of solid areas alternating with cystic areas and pseudopapillary formations with evidence of cellular degeneration. Controversy still exists about the pathological factors signifying the prognosis of the disease. Nishihara et al have reported that venous invasion, degree of nuclear atypia, mitotic rate and presence of necrobiotic cell nests are helpful in determining prognosis.⁶ However Jaksic et al could not find these factors to correlate with the prognosis.⁷

Adjuvant chemotherapy has a limited role as the tumor has a low malignant potential and surgical resection is generally curative.

CONCLUSION

In conclusion, solid pseudopapillary tumour of the pancreas is a rare tumour of the pancreas. The importance of its differentiation from adenocarcinoma is emphasized as surgical resection of the tumour is curative.

REFERENCES :

1. Campagno J, Oertel JE, Kemzar M: Solid and papillary epithelial neoplasm of pancreas, probably of small duct origin: a clinicopathological study of 52 cases. *Lab Invest* 1979;40:248-49.
2. Sclafani LM, Reuter VE, Coit DG, Brennan MF: The malignant nature of papillary and cystic neoplasm of the pancreas. *Cancer* 1991; 68: 153-58.
3. Frantz VK: Tumors of pancreas. In: *Atlas of Tumor Pathology*. Washington, DC: Armed Forces Institute of Pathology 1959:32-33.
4. Sheehan M, Latona C, Aranha G, Pickleman J: The increasing problem of unusual pancreatic tumors. *Arch Surg* 2000;135:644-68.
5. Martin RCG, Klimstra DS, Brennan MF, Conlon KC: Solid pseudopapillary tumor of pancreas: a surgical enigma? *Ann Surg Oncol* 2002;9:35-40.
6. Nishihara K, Nagoshi M, Tsuneyoshi M: Papillary cystic tumor of pancreas. Assessment of their malignant potential. *Cancer* 1993;71:82-92.
7. Jaksic T, Yaman M, Thorner P, Weson DK, Filler Rm, Shandling B: A 20 year review of pediatric pancreatic tumors. *J Pediatr Surg* 1992;27:1315-17.