

Case Report-I

Squamous Cell Carcinoma in Bladder Extrophy

ALTAF GAUHAR HAJI, K. CHITRATHARA, SHEKHAR SHARMA,
D.K. VIJAYKUMAR AND V.P GANGADHARAN

ABSTRACT

Extrophy of the bladder is a rare congenital anomaly with an incidence of about 1/50000 newborn. Malignant potential of ectopic mucosa is high. Sixty percent of cancers in ectopic bladder occur during fourth and fifth decade of life, majority being adenocarcinoma (95%). Here we report a case of squamous cell carcinoma of ectopic urinary bladder in a 74-year-old male patient. In view of locally advanced disease, he received neoadjuvant chemotherapy with poor response. He underwent total cystectomy with ileal conduit diversion and continues to be alive and disease free at 36 months interval. The case is being reported on account of its rarity. Pertinent literature is being reviewed.

INTRODUCTION

Exstrophy of the bladder is a rare congenital anomaly with an incidence of about 1 per 50000 newborns. Malignant potential of the exstrophied bladder mucosa is well known; 95% are adeno-carcinomas; and 3 to 5% are squamous cell carcinomas^{1,2}. Here we report a case of squamous cell carcinoma of the exstrophied bladder that occurred in a man in mid seventies.

Case: A 74-year old healthy male, who lived with an exstrophied bladder [exstrophy-epispadiasis complex], reported with history of bleeding from the site of bladder exstrophy. He had noticed a growth like change in the

exstrophied bladder, progressive in nature about 1-year prior to the presentation (fig. 1); It had started bleeding at the time of presentation.

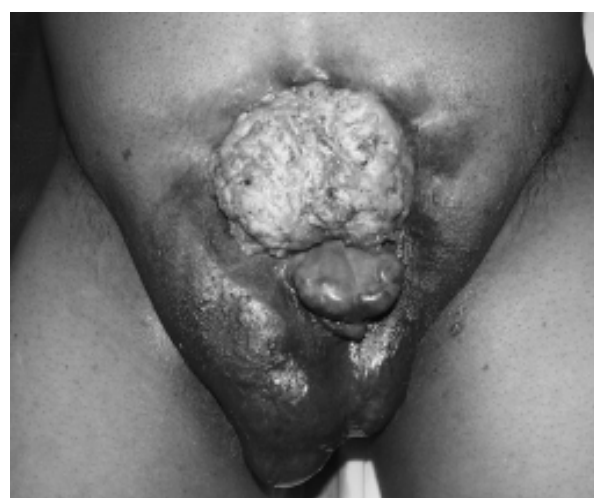

Fig 1: pre-operative photograph showing tumour

Examination revealed a short well-built man. Local examination of the lower abdomen presented a classical exstrophy – epispadiasis complex in the supra-pubic region of the anterior abdominal wall with fierce looking growth in the ectopia vesicae. The whole bladder area was filled with the tumour measuring about 15 cm x 10 cm. Ureteric orifices were not discernibly visible. Careful examination could only reveal the spillage out of urine in between the growth. Growth was not extending into the urethra and scrotum was normal with normally descended testes. Per – rectal examination revealed no pelvic masses.

Rest of the systemic examination was within normal limits. Patient had no known comorbid illnesses. Contrast enhanced CT scan of the abdomen showed classical deformities of Exstrophy – Epispadiasis complex with a growth

Department of Surgical oncology (Altaf Gauhar Haji, K. Chitrathara, Shekhar Sharma, D.K. Vijaykumar) Amrita Institute of Medical Sciences Dept of Medical Oncology (V.P Gangadharan), Lakeshore Hospital Kochi, Kerala, Pin. 682 026 INDIA

Correspondence to: **ALTAF GAUHAR HAJI**

Email: altafhaji786@yahoo.com

in bladder exstrophy invading deep muscles causing obstruction of bilateral ureteric orifices with resultant bilateral hydronephrosis. No grossly enlarged lymph nodes in inguinal, iliac or retroperitoneal region or any lesion in the liver were noted. Chest x ray was normal. The patient was planned for neoadjuvant chemotherapy and received two cycles with Gemcitabine & Cisplatin. However, a reassessment after two courses of chemotherapy did not show a measurable tumour regression. He was taken up for surgery.

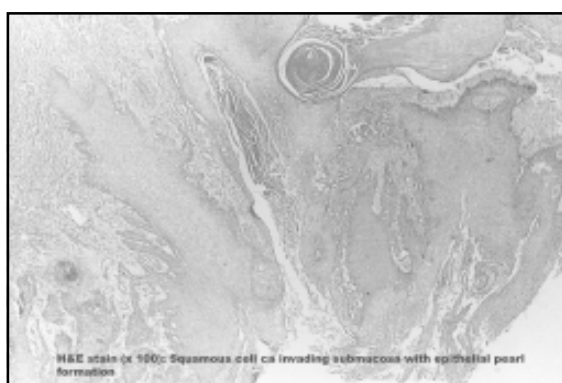


Fig 2: Histopathology showing squamous cell carcinoma involving submucosa

On surgery, a wide excision of the tumour along with exstrophy-epispadias complex (entailing total cystectomy) was done along with an ileal conduit urinary diversion using Becker uretero-intestinal anastomosis method. Reconstruction of the lower anterior abdominal fascia defect was undertaken with marlex mesh with the scrotal skin being advanced to partly cover the skin defect. Post operatively the patient had an uneventful recovery.

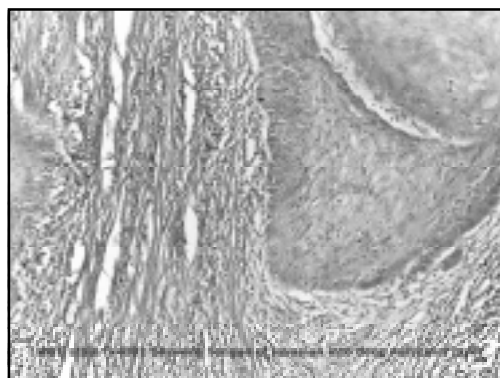


Fig 3: Histopathology showing squamous cell carcinoma invading into deeper muscle

Histopathology report showed a well differentiated squamous cell tumour (fig. 2 & 3) of size 11x14.5 cm with invasion into the deeper layers of muscle (fig. 3) along with occasional areas of perivesical fat infiltration (pT3a). The tumour showed areas of pearl formation (fig. 2) and was seen to involve the uretero-vesical junction bilaterally, the cut margins of both ureters were free.

Post operative US Scan of the abdomen showed a marked reduction in the hydronephrosis. Renal function parameters were within normal range. The patient is on regular follow up and continues to be disease free at 36 months of surgery.

DISCUSSION

Squamous cell carcinoma of urinary bladder is infrequent. A frequency of 3% (United States) to 40% in middle east (Egypt) has been reported. In exstrophy bladder about 3 to 5% are of squamous histology.^{1,2}

Chronic irritation and infection leading to metaplastic transformation of urothelium resulting in malignant changes is most likely possibility. Malignant degeneration of embryonic rests of gastrointestinal tissue can give rise to adenocarcinoma. It is also suggested that adenocarcinoma in exstrophic bladder originates from the colonic epithelium covering the mucosa of the organ.³ Majority (60%) of the malignant tumours in ectopic bladder occur during fourth and fifth decade of life and out of the remaining, about 20% each occur after 60 years and before 40 years.

Even though squamous cell carcinoma [SCC] of urinary bladder is considered as a separate entity, the treatment remains similar to transitional cell carcinoma [TCC].⁵ The prognosis is reported to be poor due to advanced stage at detection.⁶

Systemic chemotherapy regimens used to treat transitional cell carcinoma are generally ineffective for tumours with non-urothelial

histology such as adenocarcinoma or SCC.^{7,8} However overall experience with chemotherapy in non-urothelial carcinomas is limited. The gold standard of treatment of SCC of bladder is radical cystectomy with no established guidelines for any adjuvant or neoadjuvant therapy.⁷ Radiation is used for cases found inoperable or where patient is reluctant for surgery.

About 115 cases of cancer in exstrophic bladder have been reported.^{10,11} There are no comprehensive guidelines on role of adjuvant or neoadjuvant chemotherapy.

Kassouf et al reported their experience with 27 cases of pure squamous cell histology of non-bilharzial etiology over a 15-year period at MD Anderson Cancer Center.¹² They reported a 2-year overall survival of 47.6% with a median recurrence free survival of 5.1 months. For eight patients who recieved pre-operative chemotherapy, five progressed. Authors concluded that radical cystectomy remains the mainstay of treatment with locoregional recurrence being the most common cause of failure. Hayashi et al in a report of 18 cases of SCC bladder observed that radiation and cisplatin-based chemotherapy were effective supportive therapy to improve the prognosis.¹³

Present case, to our knowledge is the oldest patient to present with primary squamous cell carcinoma of an unreconstructed exstrophic bladder.¹¹

Chemotherapy was given due to locally advanced disease T2b disease (tumour infiltrating more than half the muscle thickness) with ureteric involvement together with unwillingness on the part of patient to accept surgery. The choice of Gemcitabine & Cisplatin was guided by available literature reports for palliative chemotherapy in bladder cancer.^{7,8} In view of poor response, patient was subjected to surgery, the disease free survival of 36 months along with the comfort of being dry with

ileostomy bag has made the whole exercise meaningful.

REFERENCES:

1. de Riese WD, Warmbold H: Adenocarcinoma in extrophy of the bladder; a case report and review of the literature. *Int Urol Nephrol* 1986;18(2):159-162.
2. Gupta S, Gupta IM: Ectopia vesica complicated by Squamous cell carcinoma; *Br J Urol* 1976;48:224.
3. Facchini V, Gadduchi A, Colombi L, et. al. Carcinoma developing in bladder extrophy. *Br J Obstet Gynecol* 1987;94:795-797.
4. Brodsky GL. Pathology of bladder carcinoma. *Hematol Oncol Clin North Am* 1992;6:59-80.
5. Serreta V; Pomara G; Piazza F; Gange E: Pure squamous cell carcinoma of the bladder in western countries. *Eur Urol* 2000;37(1):85-9.
6. Kochakarn W, Kongchareonsombat W, Tirapanich W: Squamous cell carcinoma of the eviscerated bladder: a case report. *J Med Assoc Thai* 2001;84(5):735-7.
7. Montie JE, Eisenberger MA, et al. NCCN Clinical Practice Guidelines in Oncology: Bladder Cancer (including Upper tract tumours and Urothelial Carcinoma of Prostate); V.2.2008. Available online at http://www.nccn.org/professionals/physician_gls/PDF/bladder.pdf
8. Seifker-Ratke AO, Dinney CPN, Czerniak B, Milikan RE. Bladder Cancer: In MD Anderson Manual of Medical Oncology. Kantarjian HM, Wolf RA, Koler CA editors. 1st Edition. Tata McGraw Hill Publishers, New Delhi; 2007:739-756.
9. Inui M, Fujita K, Ueda N, Takenaka I, Kakehi Y: A case of regionally metastatic pure squamous cell carcinoma of the urinary bladder successfully treated with radical chemoradiotherapy. *Hinyokika Kiyo* 2000;48(1):33-5.
10. Rieder JM, Parsons JK, Gearhart JP, Schoenberg M Primary squamous cell carcinoma in unreconstructed exstrophic bladder. *Urology* 2006;67(1):199-200.
11. Ribeiro JC, Silva C, Sousa L, García P, Santos A. Squamous cell carcinoma in bladder exstrophy. *Actas Urol Esp* 2005;29(1):110-2.
12. Kassouf W, Spiess PE, Siefker-Radtke A, et. al. Outcome and patterns of recurrence of nonbilharzial pure squamous cell carcinoma of the bladder: a contemporary review of The University of Texas M D Anderson Cancer Center experience. *Cancer* 2007;110(4):764-9.
13. Hayashi N, Asano K, Furuta A, et. al. Invasive squamous cell carcinoma of the bladder: report of 18 cases and review of literature. *Nippon Hinyokika Gakkai Zasshi* 2004;95(5):711-7.
14. Shokeir AA: Squamous cell carcinoma of the bladder: pathology, diagnosis and treatment. *Br J Urol Int* 2004;93(8):216-220.

