

Malignant gastric teratoma in a 3-month-old infant

A 3-month-old boy presented with a rapidly growing abdominal mass noticed by his mother since 1-week, with no other significant history.

On examination, the child had a large, firm, nontender mass extending from the left hypochondrium to the right. Lymphadenopathy or ascites was absent. Alpha-fetoprotein (AFP) was markedly elevated at 18,055 ng/mL (normal 0.2-9.0 ng/mL) with normal beta human chorionic gonadotropin level.

Contrast enhanced tomography of the abdomen and chest revealed a large retroperitoneal heterogeneous mass pushing the left kidney inferiorly and displacing the gut to the right [Figure 1].

On exploration, a large intraperitoneal exophytic mass of size 8 cm × 9 cm × 8 cm was seen arising from the greater curvature and the posterior wall of the stomach occupying whole of the lesser sac [Figure 2]. It had variegated consistency with no involvement of adjacent structures and lymphadenopathy. The tumor was completely excised along with the involved gastric wall. Stomach was repaired in two layers.

Histopathology revealed cystic, solid teratoid neoplasm, and a diagnosis of grade III immature teratoma was made. The tumor was seen invading the wall of the stomach and the resection margin of the stomach was free.

Postoperatively child remained healthy, and AFP levels came down to 5300 ng/mL. Child has been on regular follow-up for past 2 years with no recurrence.

Praveen Kishore, Prashant Jain¹

Departments of Paediatrics and ¹Paediatric Surgery and Paediatric Urology, BLK Super Specialty Hospital, New Delhi, India

Access this article online

Quick Response Code:



Website:
www.ijmpo.org

DOI:
10.4103/0971-5851.171554

Address for correspondence:

Dr. Praveen Kishore,
Clinical Fellow (Neonatology), St Michaels Hospital,
BS2 8EG, Bristol, United Kingdom.
E-mail: praveen_kmc@yahoo.com

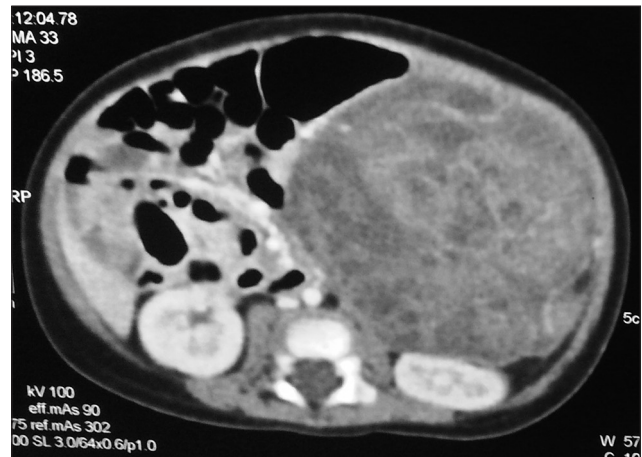

Figure 1: Axial contrast enhanced computed tomography of abdomen showing a large heterogeneous mass pushing the left kidney inferiorly and displacing the gut, no evidence of calcification

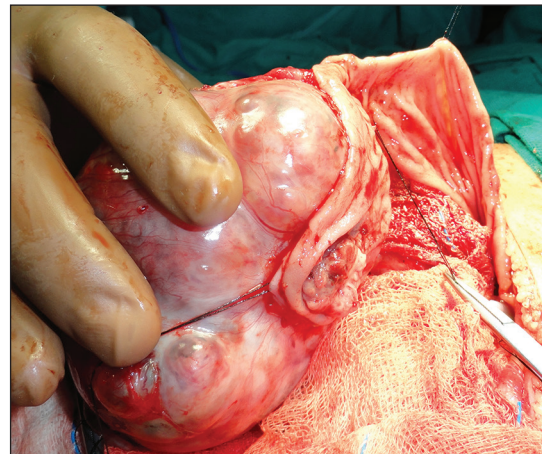


Figure 2: Intraoperative photograph demonstrating large mass arising from greater curvature and posterior wall of stomach

This is an open access article distributed under the terms of the Creative Commons Attribution-NonCommercial-ShareAlike 3.0 License, which allows others to remix, tweak, and build upon the work non-commercially, as long as the author is credited and the new creations are licensed under the identical terms.