

Clinicopathological Profile of Anaplastic Lymphoma Kinase-positive Nonsmall Cell Lung Cancer: An Indian Perspective

Abstract

Background: A novel fusion gene of echinoderm microtubule-associated protein-like 4 (EML4) and anaplastic lymphoma kinase (ALK) has been identified in a subset of non-small-cell lung cancers (NSCLCs). Patients with the ALK-EML4 fusion gene demonstrate unique clinicopathological and physiological characteristics. Here we present an analysis of clinicopathological profile of patients of metastatic adenocarcinoma harboring the ALK-EML4 fusion gene. **Methods:** A retrospective analysis of advanced ALK positive NSCLC, who presented at this tertiary care hospital of armed forces from September 2014 to December 2016 was conducted. The primary goal was to evaluate demographic and clinicopathological profile of ALK positive advanced NSCLC. Detection of ALK fusion was done by IHC on formalin fixed paraffin embedded cell blocks. **Results:** Out of 270 patients of NSCLC, 15 (7.4%) tested positive for ALK-EML4 fusion. Rate of positivity was higher in females (13.7%) than in males (5%). The correlation of the ALK-EML4 fusion gene and clinicopathological characteristics of NSCLC patients demonstrated a significant difference in smoking status, histological types, stage, and metastatic pattern. **Conclusion:** Our analysis indicated that ALK-EML4 positive NSCLC comprised a unique subgroup of adenocarcinomas with distinct clinicopathological and radiological characteristics. Incidence of ALK positivity was found to be higher in females and never smokers. These patients have distinct pathological and radiological characteristics.

Keywords: Adenocarcinoma, anaplastic lymphoma kinase-echinoderm microtubule-associated protein-like 4, fluorescent *in situ* hybridization, immunohistochemistry, metastasis, nonsmall cell lung cancer

Introduction

For a long time, systemic cytotoxic chemotherapy remained the gold standard in the treatment of advanced nonsmall cell lung cancer (NSCLC) patients. With the discovery of the anaplastic lymphoma kinase (ALK) gene in NSCLC and the development of crizotinib against this subset of NSCLC, an era of targeted therapies took the lead way.^[1,2] The echinoderm microtubule-associated protein-like 4 (EML4) – ALK is a fusion-type protein tyrosine kinase, found in 4%–5% of NSCLC.^[3] The ALK gene arrangements are largely mutually exclusive with epidermal growth factor receptor (EGFR) or Kirsten ras mutations.^[4] Immunohistochemistry (IHC), fluorescent *in situ* hybridization, and reverse transcription polymerase chain reaction have been used to detect ALK mutation. The presence of an ALK fusion oncogene defines a molecular subset of NSCLC with distinct clinical and

pathological features. This subset of patients are characterized by relatively younger age, nonsmokers or light smokers, and a mucinous, cribriform, or signet-ring cell subtype of adenocarcinoma.^[5] Whenever possible, therapy of patients with advanced NSCLC should be individualized, based on the molecular and histological features of the tumor. ALK is a straightforward, biology-based biomarker, predicting a high response rate with crizotinib even in heavily pretreated patients and is relatively nontoxic. This study was aimed to analyze data and provide a better understanding of patients with ALK-positive advanced NSCLC.

Objective

To evaluate the epidemiological, clinicopathological profile, and disease characteristics of advanced EML4-ALK-positive NSCLC patients in a tertiary care hospital for armed forces.

AP Dubey,
Nikhil Pathi,
Anvesh Rathore,
S Viswanath,
Abhishek Pathak,
Rahul Sud, SK Rai¹

Departments of Medical Oncology and ¹Department of Medicine, Army Hospital, Research & Referral, New Delhi, India

Address for correspondence:

Dr. AP Dubey,
Army Hospital
(Research and Referral),
Delhi Cantt., New Delhi, India.
E-mail: ambydubey@gmail.com

Access this article online

Website: www.ijmpo.org

DOI: 10.4103/ijmpo.ijmpo_19_17

Quick Response Code:



How to cite this article: Dubey AP, Pathi N, Rathore A, Viswanath S, Pathak A, Sud R, *et al.* Clinicopathological profile of anaplastic lymphoma kinase-positive nonsmall cell lung cancer: An Indian perspective. Indian J Med Paediatr Oncol 2018;39:32-5.

This is an open access article distributed under the terms of the Creative Commons Attribution-NonCommercial-ShareAlike 3.0 License, which allows others to remix, tweak, and build upon the work non-commercially, as long as the author is credited and the new creations are licensed under the identical terms.

For reprints contact: reprints@medknow.com

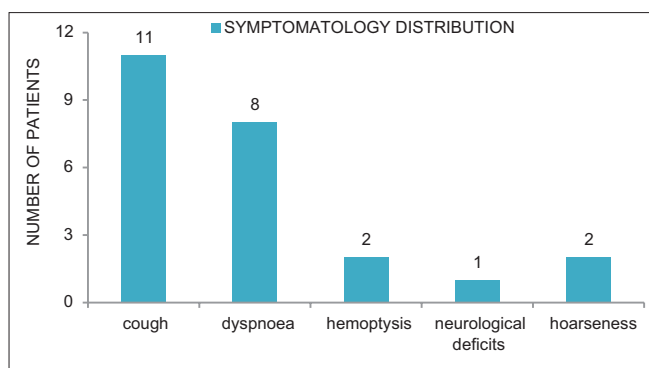


Figure 1: Symptomatology

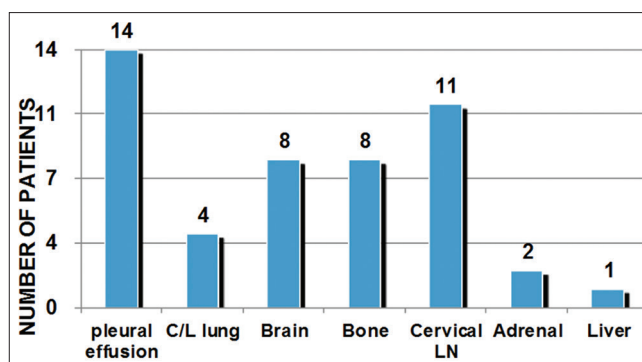


Figure 2: Sites of metastasis

Table 1: Demographic and clinical profile of anaplastic lymphoma kinase-positive nonsmall cell lung cancer patients

Characteristic	Number(%)
NSCLC patients	
Study population	203
Male:female	2.7:1 (148/55)
Smoker (all male) (%)	45 (30)
ALK-positive NSCLC patients	15/203 (7.3)
Median age (years)	39.5
Male:female	1:1.2 (7/8)
Smoker/tobacco user (%)	3 (20)
Comorbidities (%)	
Hypertension	2 (13)
Chronic kidney disease	1 (7)
ECOG PS (%)	
0-1	13 (86)
2	1 (7)
>2	1 (7)
Clinical features (%)	
Cough	11 (73)
Dyspnea	8 (53)
Hemoptysis	2 (13)
Hoarseness	1 (7)
Neurological deficits	2 (13)

ALK – Anaplastic lymphoma kinase; NSCLC – Nonsmall cell lung cancer; ECOG – Eastern Cooperative Oncology Group; PS – Performance status

Materials and Methods

A retrospective analysis of advanced ALK-positive NSCLC who presented at this tertiary care hospital of armed forces from September 2014 to September 2016 was conducted. The primary goal was to evaluate demographic and clinicopathological profile of ALK-positive advanced NSCLC. Details of these patients were obtained from prospective lung cancer audit database that is maintained in the department of medical oncology. Patients underwent a complete history and physical examination, routine blood testing (complete hemogram, renal and liver function tests). Tumor staging was performed by contrast-enhanced computed tomography chest and abdomen, whole body

positron emission tomography-computed tomography, and magnetic resonance imaging brain. Detection of ALK fusion was done by IHC on formalin-fixed paraffin-embedded cell blocks.

Observation

Out of 203 NSCLC patients evaluated, 15 patients (7.3%) tested positive for ALK rearrangements. The median age of ALK-positive NSCLC cases was 39.5 years (range 29–63 years), with a slight female predominance (male: female = 1:1.2) [Table 1]. Smoking history was noted in 20% of all ALK+ cases. There were no female smokers in the study. Thirteen patients (86%) had an Eastern Cooperative Oncology Group performance status 0–1. The most common presentation was cough observed in 73% (11) patients followed by shortness of breath noted in 53% (8) cases [Figure 1]. Hemoptysis and neurological deficits were presenting complaints in 13% of cases each. One patient was a diagnosed case of chronic kidney disease Stage IV on maintenance hemodialysis. Two cases were known hypertensives on antihypertensives. Histologically, adenocarcinoma was the dominant subtype found in 73% (11) of all cases and rest about 26% of them were poorly differentiated carcinoma [Table 2]. Six (55%) of the cases were having mucinous or signet-ring pattern on histology. At baseline, one patient was having Stage III disease with rest 93% (14) were Stage IV disease. Eleven (73%) of the patients had more than 2 sites of metastases, with median number of metastasis equal to three. Most common site of metastases was pleural effusion/pleural deposits (93%, $n = 14$) followed by brain and bony mets (53%, $n = 8$) as shown in Figure 2. On radio imaging, all the brain metastases were present in anterior cranial fossa. Primary tumor location was central in 66% ($n = 10$) whereas peripheral and multiple lesions in 13% ($n = 2$) and 20% ($n = 3$), respectively.

Discussion

Lung cancer is the most prevalent cancer and leading cause of cancer-related deaths worldwide.^[6] Despite improvements in therapeutic methodology, including surgery, chemotherapy, and radiotherapy, the average

Table 2: Tumor characteristics of anaplastic lymphoma kinase-positive nonsmall cell lung cancer patients

Characteristic	Number(%)
Histology (%)	
Adenocarcinoma	11/15 (73)
Mucinous	3/11 (27)
Signet ring	3/11 (27)
Poorly differentiated	5/11 (45)
Poorly differentiated carcinoma	4/15 (26)
Stage (%)	
III	1 (7)
IV	14 (93)
Median number of metastatic sites (%)	-
<2 sites	4 (26)
2-4 sites	11 (73)
>4 sites	0
Sites of metastases (%)	-
Pleural effusion	14 (93)
Contralateral lung	4 (26)
Brain	8 (53)
Bone	8 (53)
Cervical node	11 (73)
Adrenals	2 (13)
Liver	1 (7)
Primary tumor location (%)	-
Central	10 (66)
Peripheral	2 (13)
Multiple	3 (20)
Intrathoracic disease (%)	2 (13)
Intra- and extra-thoracic disease (%)	13 (87)

prognosis of lung carcinoma still remains unsatisfactory, and the 5-year survival rate is merely 15%.^[7] Among those lung cancer patients, NSCLC accounted for approximately 80%–85% of lung cancer cases.^[8] Increased attention has been garnered in the development and application of drugs that target specific molecules which expressed on NSCLC cells which include signaling transduction and angiogenesis inhibitors, such as the EGFR and ALK-targeted drugs.^[1,9,10]

We analyzed 203 (148 males and 55 females) patients of advanced NSCLC for the presence of EGFR mutations and ALK rearrangement from April 2014 to December 2016. ALK testing was done with IHC on formalin-fixed paraffin-embedded blocks. Fifteen (7.3%) patients tested positive for ALK-EML4 translocation, which was consistent with the previous published reports.^[11,12] Although our study had nearly equal number of males and females testing positive for ALK translocation, the incidence was higher in females (14%), whereas incidence in males was found to be 4.7%, which was statistically significant (7/141 vs. 8/47, $P = 0.03$). This finding was in contrast with prior studies which found male preponderance in patients with ALK-positive NSCLC, those being light or never smokers. All females were never smokers in our study whereas

smoking history was present in around 42% of males. The incidence of ALK positivity was independent of smoking status in males. The median age of ALK positive patients was found to be 39.5 years which is less than that of non ALK translocated patients, which is consistent with published literature but lower than other studies where the median age was found to be 52 years.^[13] The most common symptoms were cough (73%) and dyspnea (53%) which were similar to non-ALK-positive patients of carcinoma lung.^[14] On histopathology, out of fifteen patients, 11 (73%) were adenocarcinoma and rest four were poorly differentiated carcinoma. Mucinous and signet-ring pattern together combined was present in 6 (54%) of 11 patients of adenocarcinoma, with rest 5 (45%) being adenocarcinoma of poorly differentiated type. The solid growth pattern with signet-ring cell component, a feature not often seen with EGFR mutant or wild-type NSCLC, and mucinous cribriform pattern with extracellular mucinous materials are the major histological findings published in literature.^[15-17] The anatomical location of ALK+ lung cancers appears to be more central, and subsequently, bronchoscopic cytology positivity is more common in the ALK-positive group of patients as compared to non-ALK-positive group of adenocarcinoma patients. Ten (66%) patients had central location on radio imaging; rest 2 (13%) and 3 (20%) had peripheral and multiple lesions, respectively. Yang *et al.* found higher incidence of extrathoracic metastasis in ALK-positive cases, which was consistent in our study group with extrathoracic disease present in 13 (87%) of 15 patients.^[18] Eleven (73%) had disseminated disease with more than two sites of metastasis. Most ALK-positive patients have predilection for cerebral and skeletal metastases in addition to pleural and pericardial effusions.^[12,15] This finding was not significantly different in our patients, with pleural effusion being most common site of metastasis, followed by brain and bony metastasis. Pleural involvement in the form of moderate to massive pleural effusion or pleural deposits was the most common site of metastasis found in 14 (93%) patients. Other common sites of metastasis were bone and brain in 8 (53%) patients each. In contrast, liver metastasis was present only in one patient of our study group.

Limitation of our study was it consisted of only 203 patients, out of which only 15 were found positive for ALK-EML4 fusion protein. Ratio of males and females was unequal, reason being this hospital catering for serving army personnel and their dependents and also incidence of carcinoma lung being less common in females.

Conclusion

Our analysis indicated that ALK-EML4-positive NSCLC comprised a unique subgroup of adenocarcinomas with distinct clinicopathological characteristics. Compared to non-ALK-positive NSCLC, this group is significantly enriched for nonsmoking patients with adenocarcinoma.

The positive rate of the ALK-EML4 fusion gene expression in females was found to be higher than that in males which was statistically significant. Mucinous and signet-ring pattern was present in more than half of adenocarcinomas. ALK-positive tumors have propensity to have central lesions in contrast to non-ALK-positive adenocarcinomas. They have disseminated disease with a typical metastatic pattern with pleural involvement being the most common site, followed by brain and skeletal metastasis. The molecular target regimens that target the ALK-EML4 fusion protein would be an effective, novel therapeutic modality for these patients, which may turn out to be more effective and with less side effects than conventional treatment.

Financial support and sponsorship

Nil.

Conflicts of interest

There are no conflicts of interest.

References

- Soda M, Choi YL, Enomoto M, Takada S, Yamashita Y, Ishikawa S, *et al.* Identification of the transforming EML4-ALK fusion gene in non-small-cell lung cancer. *Nature* 2007;448:561-6.
- Bunning K, Smith C, Kennedy P, Greenham C. Examination of the communication interface between students with severe to profound and multiple intellectual disability and educational staff during structured teaching sessions. *J Intellect Disabil Res* 2013;57:39-52.
- Horn L, Pao W. EML4-ALK: Honing in on a new target in non-small-cell lung cancer. *J Clin Oncol* 2009;27:4232-5.
- Takahashi T, Sonobe M, Kobayashi M, Yoshizawa A, Menju T, Nakayama E, *et al.* Clinicopathologic features of non-small-cell lung cancer with EML4-ALK fusion gene. *Ann Surg Oncol* 2010;17:889-97.
- Gainor JF, Varghese AM, Ou SH, Kabraji S, Awad MM, Katayama R, *et al.* ALK rearrangements are mutually exclusive with mutations in EGFR or KRAS: An analysis of 1,683 patients with non-small cell lung cancer. *Clin Cancer Res* 2013;19:4273-81.
- Jemal A, Bray F, Center MM, Ferlay J, Ward E, Forman D, *et al.* Global cancer statistics. *CA Cancer J Clin* 2011;61:69-90.
- Jemal A, Siegel R, Ward E, Murray T, Xu J, Smigal C, *et al.* Cancer statistics, 2006. *CA Cancer J Clin* 2006;56:106-30.
- Ettinger DS, Bepler G, Bueno R, Chang A, Chang JY, Chirieac LR, *et al.* Non-small cell lung cancer clinical practice guidelines in oncology. *J Natl Compr Canc Netw* 2006;4:548-82.
- Miller VA, Kris MG, Shah N, Patel J, Azzoli C, Gomez J, *et al.* Bronchioloalveolar pathologic subtype and smoking history predict sensitivity to gefitinib in advanced non-small-cell lung cancer. *J Clin Oncol* 2004;22:1103-9.
- Tiseo M, Gelsomino F, Boggiani D, Bortesi B, Bartolotti M, Bozzetti C, *et al.* EGFR and EML4-ALK gene mutations in NSCLC: A case report of erlotinib-resistant patient with both concomitant mutations. *Lung Cancer* 2011;71:241-3.
- Takeuchi K, Choi YL, Soda M, Inamura K, Togashi Y, Hatano S, *et al.* Multiplex reverse transcription-PCR screening for EML4-ALK fusion transcripts. *Clin Cancer Res* 2008;14:6618-24.
- Shaw AT, Yeap BY, Mino-Kenudson M, Digumarthy SR, Costa DB, Heist RS, *et al.* Clinical features and outcome of patients with non-small-cell lung cancer who harbor EML4-ALK. *J Clin Oncol* 2009;27:4247-53.
- Shaw AT, Solomon B. Targeting anaplastic lymphoma kinase in lung cancer. *Clin Cancer Res* 2011;17:2081-6.
- Corner J, Hopkinson J, Fitzsimmons D, Barclay S, Muers M. Is late diagnosis of lung cancer inevitable? Interview study of patients' recollections of symptoms before diagnosis. *Thorax* 2005;60:314-9.
- Rodig SJ, Mino-Kenudson M, Dacic S, Yeap BY, Shaw A, Barletta JA, *et al.* Unique clinicopathologic features characterize ALK-rearranged lung adenocarcinoma in the Western population. *Clin Cancer Res* 2009;15:5216-23.
- Yoshida A, Tsuta K, Watanabe S, Sekine I, Fukayama M, Tsuda H, *et al.* Frequent ALK rearrangement and TTF-1/p63 co-expression in lung adenocarcinoma with signet-ring cell component. *Lung Cancer* 2011;72:309-15.
- Wong DW, Leung EL, So KK, Tam IY, Sihoe AD, Cheng LC, *et al.* The EML4-ALK fusion gene is involved in various histologic types of lung cancers from nonsmokers with wild-type EGFR and KRAS. *Cancer* 2009;115:1723-33.
- Yang P, Kulig K, Boland JM, Erickson-Johnson MR, Oliveira AM, Wampfler J, *et al.* Worse disease-free survival in never-smokers with ALK+ lung adenocarcinoma. *J Thorac Oncol* 2012;7:90-7.