

Case Report

Successful Usage of External Beam Radiation to Myeloma Cutaneous Lesions in Patient with Refractory, Relapsed Multiple Myeloma

Abstract

Cutaneous myeloma lesions are rare. External beam radiation is effective in inducing remission in cutaneous myeloma lesions.

Keywords: Cutaneous myeloma, external beam radiation, skin involvement in myeloma

Introduction

Direct cutaneous involvement in multiple myeloma (MM) is rare and usually associated with clinically aggressive behavior.^[1] It has been associated with advanced stage, a high-tumor burden, and poor prognosis.^[1] Clinically, it appears as a nodular skin lesions that involve a well-demarcated area of the skin. Here, we report the case of a 73-year-old male patient with MM who developed cutaneous lesions on the leg and was treated successfully, with radiation therapy (RT).

Case Report

In July 2013, a 73-year-old, elderly, frail male with performance status ECOG III, presented to us, postvertebroplasty. We confirmed the diagnosis of MM, Stage IIIA, based on bone marrow plasmacytosis, M spike on serum protein electrophoresis (SPE), and multiple osteolytic lesions. He had normal creatinine, calcium, and uric acid.

He was initiated on bortezomib and dexamethasone weekly induction and after 4 weeks, as he improved clinically, switched to monthly triple induction regimen (Bortezomib, Melphalan, and Prednisone). Complete remission was seen after 12 cycles of treatment, by the absence of M spike on SPE.

At this point of time, he developed symptomatic triple-vessel coronary disease and underwent five-graft coronary bypass surgery successfully in June 2014.

This is an open access journal, and articles are distributed under the terms of the Creative Commons Attribution-NonCommercial-ShareAlike 4.0 License, which allows others to remix, tweak, and build upon the work non-commercially, as long as appropriate credit is given and the new creations are licensed under the identical terms.

For reprints contact: reprints@medknow.com

After he recovered completely from the surgery, he was kept on lenalidomide maintenance for another 12 months and stopped afterward.

In May 2016, relapse of myeloma was confirmed on fine-needle cytology from right clavicular swelling and reemergence of M spike on SPE. He received radiation to the clavicular lesion and was initiated on monthly bortezomib, oral cyclophosphamide, and prednisone. Clavicular lesion regressed completely, and M spike showed a partial response, after 6 months of treatment.

In December 2016, he developed multiple painless, nonpruritic, firm, variegated, purplish colored, and papulonodular lesions approximately 3–12 mm in maximum diameter forming a conglomeration of 16 cm × 5 cm cutaneous lesions on his right anterior leg below the right knee [Figure 1]. He denied the history of allergic reactions, skin infection, inflammatory disease, or trauma to the affected region of the leg. The rest of his physical examination was within normal limits.

A punch biopsy of the lesion revealed myelomatous plasma cells in the dermis and deep dermis confirming cutaneous involvement [Figures 2 and 3].

On radiological evaluation with computed tomography (CT), the underlying bone below the skin lesions was uninvolved.

He was commenced on external beam RT (EBRT). We selected electron beam therapy as the cutaneous lesions were

Chira Ranjan Khadanga, B Saikumar¹, K Sujatha², Anand Kumar Vaggu³, Sambasivaiah Kuraparthi¹

Departments of Radiation Oncology, ¹Medical Oncology, ²Pathology and ³Dermatology, Krishna Institute of Medical Sciences, Secunderabad, Telangana, India

Address for correspondence:
Dr. Sambasivaiah Kuraparthi,
Department of Medical Oncology, Krishna Institute of Medical Sciences, Secunderabad - 500 003, Telangana, India.
E-mail: sambasvims@yahoo.co.in

Access this article online

Website: www.ijmpo.org

DOI: 10.4103/ijmpo.ijmpo_140_17

Quick Response Code:



How to cite this article: Khadanga CR, Saikumar B, Sujatha K, Vaggu AK, Kuraparthi S. Successful usage of external beam radiation to myeloma cutaneous lesions in patient with refractory, relapsed multiple myeloma. Indian J Med Paediatr Oncol 2019;40:S136-8.

mostly superficial (involving the dermis and deep dermis). CT-based RT simulation was done in the supine position with left leg abducted and slightly externally rotated to keep the contralateral leg away from the electron beam. Thin axial sections CT images were acquired after intravenous contrast injection from mid-thigh to foot. Images were transferred to treatment planning system, and three-dimensional reconstruction was done. A single enface portal with 6 MeV, energy electron beam, was selected ensuring adequate coverage of the affected skin. A tissue-equivalent bolus of 5-mm thickness was also kept over the skin to deliver adequate dose to the skin lesions. Dosimetric plan evaluation with different parameters was done ensuring adequate coverage of the targets [Figures 4 and 5]. He received a total dose of 33 Gy in 11 daily fractions over 13 days. He tolerated the treatment without significant acute RT toxicity. On follow-up after 6 weeks, complete regressions of the lesions were observed without any late RT toxicity except mild hyperpigmentations over the affected area.

Subsequently, as pomalidomide has become available in India, he was commenced on pomalidomide 4 mg daily. He could undergo cataract surgery with intraocular lens placement without any complications.

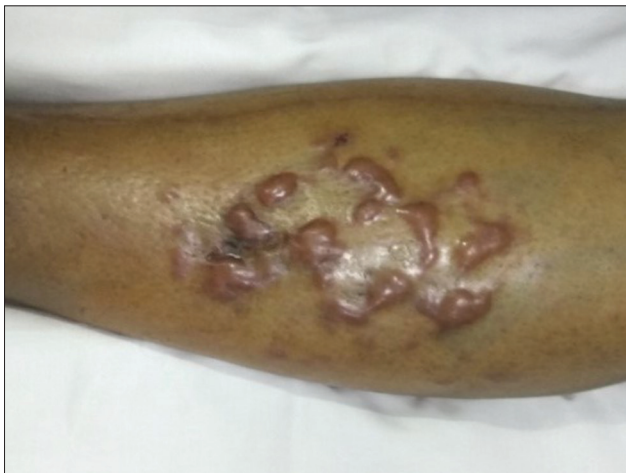

Figure 1: Skin lesions on the leg

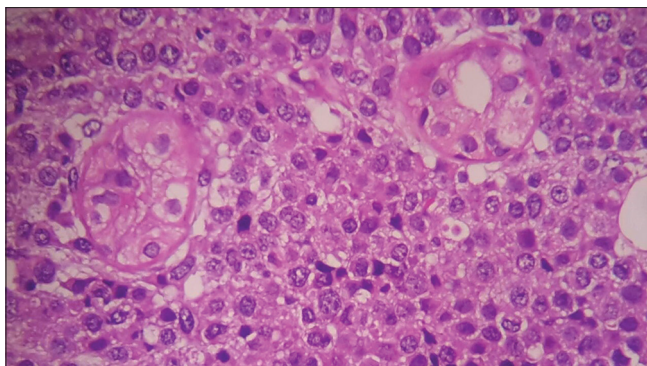


Figure 3: Infiltrating plasma cells $\times 100$

He is doing well at the time of submission of this manuscript with well-maintained blood counts and good quality of life.

Discussion

This patient exemplifies the changing paradigm in the clinical and natural course of MM. Hitherto rare sites of involvement may get involved more frequently. This case also demonstrates that interleaving of multimodality myeloma treatments can improve the outcomes significantly, more importantly, other life-threatening comorbid diseases can be approached as in nonMM patients.

MM, which comprises of 10% of all hematological malignancies, is known to affect directly various organs such as bones, kidneys, and peripheral nerves. Involvement of skin, directly by MM is rare and known to occur in 5%–10%.^[1] Although cutaneous MM has been seen at the end of natural course of the disease; rarely, it can be an initial presentation and even precede the development of MM.^[2] Furthermore, a case series of eight patients showed that the prognosis of patients with cutaneous MM is poor, despite aggressive treatment, with average overall survival of 1 year.^[1] This study also showed deletion of RB-1 gene may identify high-risk myeloma patients. Although trunk and abdomen are most frequent sites to get affected these lesions can affect skin anywhere in the body. They take the form of papules or nodules either cutaneous or

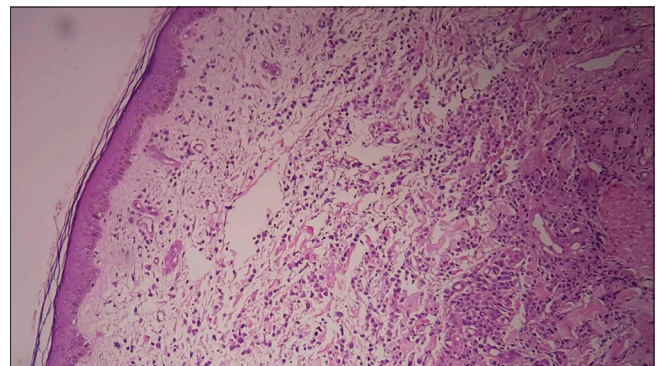


Figure 2: Biopsy from the lesion $\times 10$ power

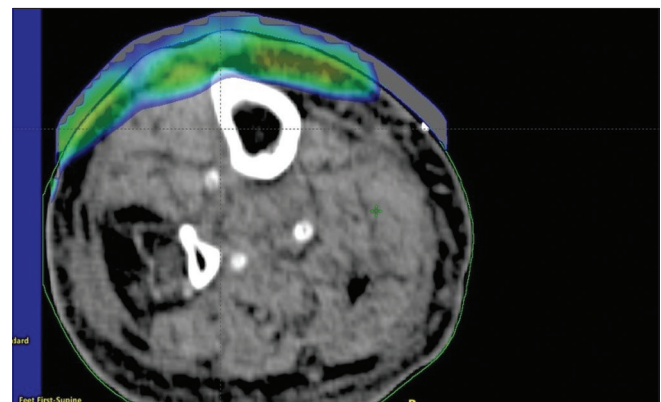


Figure 4: Axial view

