



Unilateral Interstitial Lung Disease with Contralateral Effusion: Unusual Case Report of Dasatinib Toxicity

Maheema Bhaskar¹ Pavankumar Biraris¹ Owais Tisekar¹ Rajiv Kumar Kaushal² Amit Janu³
Sandeep Tandon¹

¹Department of Pulmonary Medicine, Tata Memorial hospital and Homi Bhabha National Institute, Mumbai, Maharashtra, India

²Department of Pathology, Tata Memorial Hospital and Homi Bhabha National Institute, Mumbai, Maharashtra, India

³Department of Radiology, Tata Memorial hospital and Homi Bhabha National Institute, Mumbai, Maharashtra, India

Address for correspondence Sandeep Tandon, MD, DNB, Department of Pulmonary Medicine, Tata Memorial Hospital and Homi Bhabha National Institute, Mumbai, Maharashtra 400012, India (e-mail: sptandon@gmail.com).

Ind J Med Paediatr Oncol 2022;43:216–222.

Abstract

Dasatinib is a second-generation tyrosine kinase inhibitor (TKI) used in chronic myelogenous leukemia (CML). While pleural effusion due to Dasatinib is well described in the literature, interstitial lung disease (ILD) caused by it is rare. A 60-year-old gentleman was on treatment with 100 mg of tablet Dasatinib per day for chronic myeloid leukemia. He presented to the outpatient department with history of progressive breathlessness over 2 months. High-resolution computerized tomography (HRCT) thorax revealed mild right-sided effusion and non-specific interstitial pneumonia (NSIP) pattern of ILD in the left lower lobe. Thoracocentesis of the right-sided pleural effusion showed exudative and lymphocytic rich pleural effusion. The effusion was negative for malignant cells or infection. Biopsy of the left lower lobe was consistent with the diagnosis of ILD. He was started on prednisolone which was gradually tapered and stopped. At 3 months, there was a complete resolution of the ILD and pleural effusion. Clinicians need to be aware about the pleuroparenchymal toxicities of Dasatinib. Early diagnosis and treatment with steroids can lead to complete resolution of the signs and symptoms.

Keywords

- Dasatinib
- interstitial lung disease
- prednisolone
- chronic myelogenous leukemia

Introduction

Dasatinib is an orally active tyrosine kinase inhibitor (TKI) used as a second-line agent in chronic myelogenous leukemia (CML). It is 325 times more potent than the first-generation TKI, imatinib.¹ Like its predecessor, it inhibits the activities of BCR-ABL, c-kit, and PDGFR oncogenes. Also, it

inhibits the activities of src (v-sarcoma) family kinases, tec, and Lyn oncogenes.¹ Amongst the respiratory toxicities, pleural effusion is most common. Other pulmonary complications like interstitial lung disease (ILD), alveolar hemorrhage, pulmonary hypertension are rarely described in literature noticed on an average between 1 month and 25 months of therapy.^{2–5}

published online
February 15, 2022

DOI <https://doi.org/10.1055/s-0042-1742334>.
ISSN 0971-5851.

© 2022. Indian Society of Medical and Paediatric Oncology. All rights reserved.

This is an open access article published by Thieme under the terms of the Creative Commons Attribution-NonDerivative-NonCommercial-License, permitting copying and reproduction so long as the original work is given appropriate credit. Contents may not be used for commercial purposes, or adapted, remixed, transformed or built upon. (<https://creativecommons.org/licenses/by-nc-nd/4.0/>)

Thieme Medical and Scientific Publishers Pvt. Ltd., A-12, 2nd Floor, Sector 2, Noida-201301 UP, India

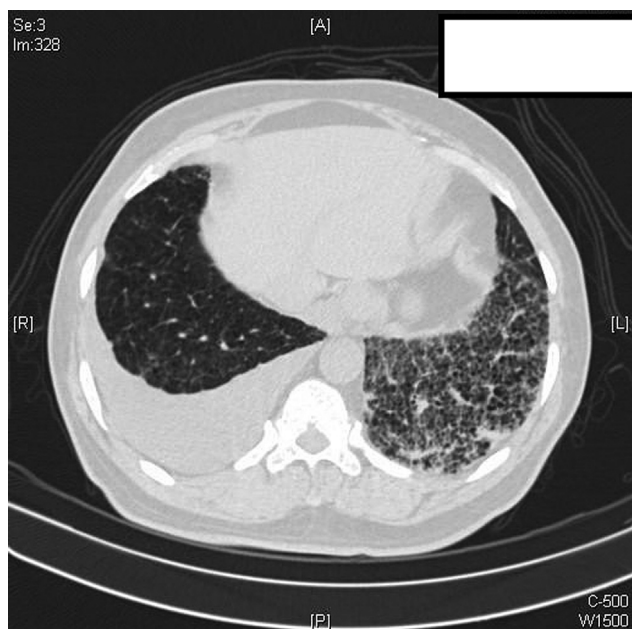

Fig. 1 High-resolution chest CT scan: interlobular septal thickening and ground-glass opacities in the left lower lobe along with right-sided pleural effusion on a background of centrilobular emphysema.

We report a case of concomitant and contralateral pleuro-pulmonary toxicity (ILD and pleural effusion) due to Dasatinib at 30 months after drug initiation.

Case Report

A 60-year-old gentleman, smoker, diagnosed with CML, was treated with 100 mg of Dasatinib daily. Patient was in CML biphenotypic blast crisis while starting Dasatinib therapy.

The BCR/ABL Ph:t (9;22) report showed a signal pattern consistent with evidence of BCR-ABL fusion Ph:t(9;22) with 9q deletion in 190/200 (95%) of cells. Ph:t (9;22) was detected in 18/20 metaphase cells. He had no other documented comorbidities except hypothyroidism. Detailed smoking history and Sokal score were not available.

Thirty months after the initiation of therapy, he presented with complaints of progressive breathlessness over 2 months. On examination, he was afebrile, tachypneic at rest with a respiratory rate of 30 breaths/min and saturation of 92% on room air. Fine end-inspiratory velcro crackles were appreciated in the left infrascapular area (ISA) with reduced breath sounds on the right ISA on auscultation. His leukocyte count was 4,800 cells/dL with 8% myelocytes and 2% metamyelocytes but no blast cells on peripheral smear. Hemoglobin was 12.4 g/dL and platelet count of 114,000/dL. The chest radiograph demonstrated reticular opacities in the left lower zone and a right-sided pleural effusion.

High-resolution computerized tomography (HRCT) thorax (→**Fig. 1**) revealed diffuse centrilobular emphysema, mild right-sided effusion and extensive reticular, interstitial septal thickening with ground-glass opacities and small patchy areas of consolidation in the left lower lobe favoring Non-Specific Interstitial Pneumonia (NSIP) pattern. The pulmonary artery to aorta diameter was less than one. Two-dimensional echo showed a normal ejection fraction and no evidence of pulmonary hypertension. Diagnostic thoracentesis of the effusion showed an exudative, lymphocytic rich (91%) pleural effusion with low adenosine deaminase (ADA) (8 IU/L). The effusion cytology was negative for malignant cells. Cultures were negative for bacteria and fungi. Investigations for tuberculosis including Xpert MTB/Rif and cultures were negative as well. Pulmonary function testing revealed a moderate restriction (forced vital capacity [FVC] 1,300 mL) in the lung capacity with

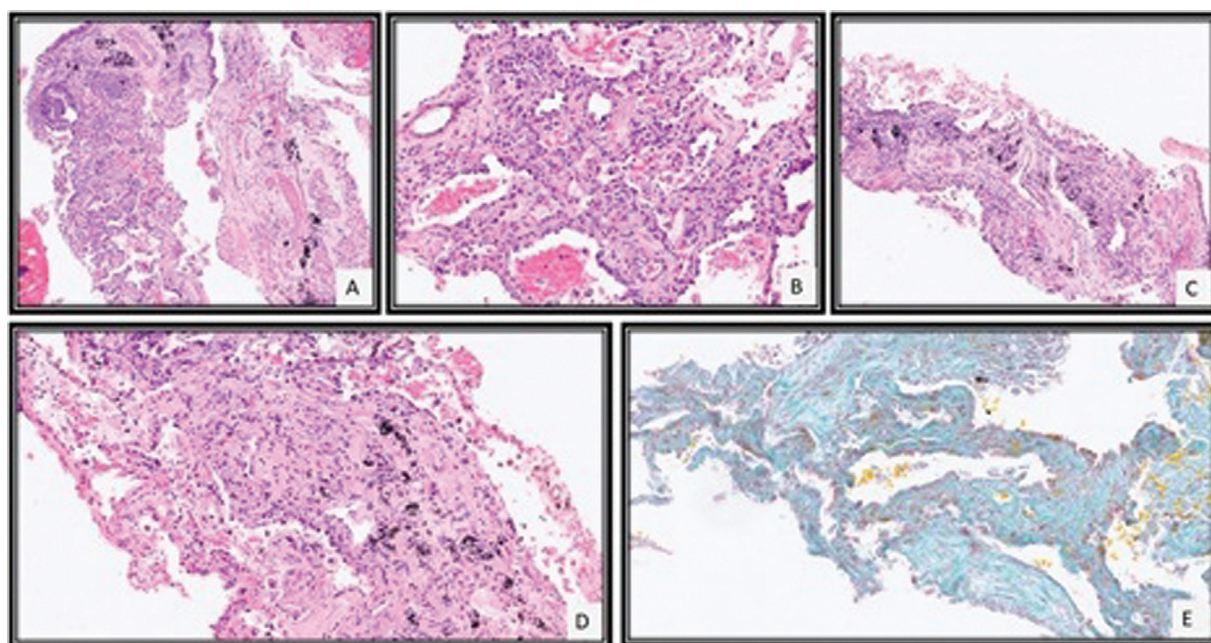


Fig. 2 CT-guided lung biopsy revealed tissue core of alveolated lung parenchyma with mild interstitial lymphocytic inflammation (A), type II pneumocyte hyperplasia (B), and mild septal widening with fibrosis (C, D) which was highlighted by special stain for Masson Trichrome (E).

severely reduced diffusion capacity (DLCO) of 36%. Rheumatological analyses like ANA, DsDNA, RA, anti-CCP, SSA, SSB, anti-Scl-70, and anti-Jo-1 were negative.

Image-guided biopsy of the left lower lobe showed focal interstitial lymphocytic inflammatory infiltrate with type II pneumocyte hyperplasia, mild septal thickening, and fibrosis (►Fig. 2). There was no evidence of infiltration by blast or myeloid precursors or granulomas. These features were consistent with NSIP like pattern of ILD.

A diagnosis of Dasatinib toxicity was made and the drug was discontinued. The patient was treated with 40 mg prednisolone initially, tapered gradually and stopped. At the 3 months follow-up, the patient's resting room air saturation had improved to 98%, FVC increased by 600 mL (FVC 1,900 mL), which was within the normal range predicted for the patient with marginally improved diffusion capacity of 40%. HRCT thorax at 3 months revealed a complete resolution of ILD and effusion (►Fig. 3). After Dasatinib discontinuation, patient was started on nilotinib 400 mg BD.

Discussion

Dasatinib is an orally active TKI, two logs more potent than its precursor, imatinib mesylate, and is indicated not only for imatinib resistant or intolerant cases of CML but also as a first-line option in CML, if clinically indicated.

Common hematological side effects of Dasatinib include myelosuppression with neutropenia and thrombocytopenia.⁶ The significant cardiothoracic adverse effects are pleural and pericardial effusions.⁷ Other side effects like pulmonary hypertension, alveolar hemorrhage, and ILD are rare in literature^{3–5,8} with most studies reporting an incidence of pleural effusion at 23 to 35% (►Table 1). Summary of important studies of Dasatinib-induced pleural effusion is described in ►Table 1.

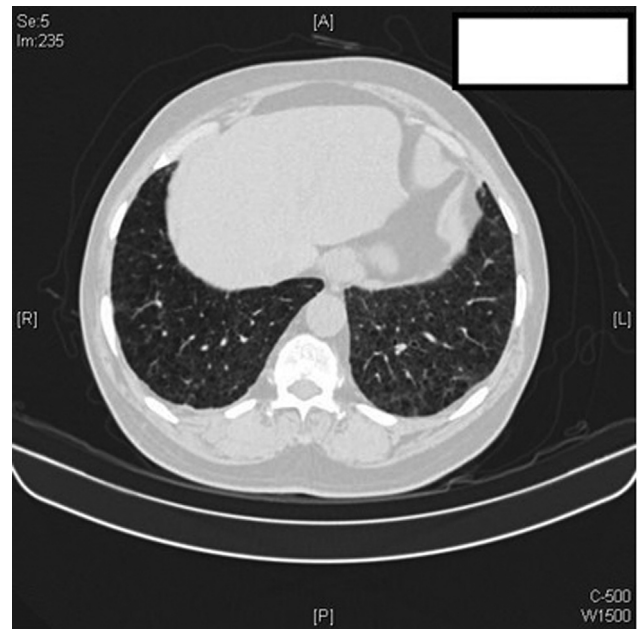


Fig. 3 High-resolution chest CT scan: significant clearing of left lower lobe interlobular septal thickening and ground-glass opacities with minimal residual right pleural thickening. Centrilobular emphysema is well appreciated here.

The suggested mechanism for the development of pleural effusion and interstitial fibrosis includes inhibition of the src family of kinase along with inhibition of phosphorylation of PDGF and proliferation of large granular lymphocytes (LGLs). The resultant pleural effusion is rich in lymphocytes, exudative in nature, and responds well to steroids, further suggesting an immunological basis for its toxicity.⁹ Nagata et al reported a higher LGL lymphocytosis in patients on Dasatinib who developed pleural effusion versus those that did not develop effusion.¹⁰

Table 1 Studies related to Dasatinib-induced pleural effusion

Publication	Total cases	Pleural effusion no. (percentage)	Median time for development of effusion (mo)	Median dose	Intervention
Iurlo et al ¹⁶	853	196 (23%)	16.6	100 mg/d	Stoppage
Cortes et al ¹⁷	259	73 (28%)	30	100 mg/d	Stoppage diuretic, steroid
Shah et al ¹⁸	670	220 (34%)	24	100 mg/d	Stoppage
Hagihara et al ¹⁹	52	17 (33%)	9	100 mg/d	Stoppage
Kantarjian et al ²⁰	316	93 (29%)	15	70–140 mg/d	Stoppage
Kim et al ²¹	34	10 (25%)	–	100 mg/d	Stoppage
Cortes et al ²²	157	45 (28%)	2.4–3	140 mg/d	Stoppage
Apperley et al ²³	174	47 (27%)	4	140 mg/d	Stoppage diuretic, steroid
Hochhaus et al ²⁴	387	106 (27%)	–	140–180 mg/d	Stoppage
Suh et al ¹¹	81	28 (35%)	6.3	100–140 mg/d	Stoppage
Fox et al ²⁵	212	53 (25%)	11	100 mg/d	Stoppage diuretic, steroid

Table 2 A literature review of Dasatinib-induced pulmonary parenchymal toxicities

Study	Patient no.	Symptoms	Time interval (days)	HRCT chest findings	Other findings	Treatment	Outcome
1. Bergerson et al ⁸	1	Dyspnea, cough	256	Bibasilar GGO Right pleural effusion	Exudate and lymphocyte rich pleural fluid	Drug interruption and reintroduction at 80 mg/d (low dose)	Resolution and no relapse after reintroduction
	2	Dyspnea, cough, myalgia	29	Diffuse GGO	–	Drug interruption	Resolution
	3	Chest pain	463	Bibasilar septal thickening	–	Drug interruption and reintroduction at 80 mg/d (low dose)	Resolution and no relapse after reintroduction
	4	Dyspnea, fever	87	Bibasilar septal thickening, right pleural effusion, and left-sided consolidation	Exudate and lymphocyte rich pleural fluid. Marked lymphocytic infiltration in surgical lung biopsy	Drug interruption	Resolution
	5	Dyspnea, cough and fever	216	Mosaic pattern	–	Prednisone @ 1 mg/kg/d and tapered over 2 mo	Resolution
	6	Cough	500	Bibasilar GGO and septal thickening with right pleural effusion	Exudate and lymphocyte rich pleural fluid	Drug interruption and reintroduction at 80 mg/d (low dose)	Resolution and no relapse after reintroduction
	7	Dyspnea, cough and chest pain	33	Bilateral pleural effusion and left lower lobe GGO	Exudate and neutrophil rich pleural fluid	Drug interruption and reintroduction at 80 mg/d (low dose).	Resolution but relapse after reintroduction
2. Radaelli et al ³	1	Fever, dyspnea,	27	Bilateral GGO and bilateral pleural effusion	–	Drug interruption with methyl prednisone @ 40 mg/d tapered over 1 mo	Resolution
3. Sakoda et al ²	1	Cough, hemoptysis, and dyspnea	365	Bilateral GGO with crazy paving pattern	–	Drug interruption and pulse methyl prednisone @ 1 g/d × 3 d and tapered over 1 mo	Resolution
4. Jasielec and Larson ⁴	1	Cough, fever, and dyspnea	Several days (not specified)	Bilateral GGO in middle and upper lobes	Transbronchial biopsy showed non-specific focal lymphocytic aggregates	Drug interruption and pulse methyl prednisone @ 1 g/d × 3 d and tapered over 1 mo	Resolution
5. Sato et al ¹²	1	Dyspnea	730	Bilateral effusion with bilateral pulmonary infiltrates	Transbronchial biopsy showed organizing pneumonia pattern	Drug interruption and treatment with corticosteroid (dose not known)	Resolution

In a case series by Bergeron et al with 8 of 40 patients receiving Dasatinib, nine developed pleuropulmonary toxicity. Six out of the nine patients developed pleural effusion (one bilateral effusion, five unilateral right-sided effusion). Seven patients had lung parenchymal changes, all bilaterally. Only four of these nine patients (one case with bilateral effusion and three with unilateral right-sided effusion) had concomitant pleural effusions along with bibasilar interlobular septal thickening, a finding suggestive of ILD. **Table 2** summarizes pulmonary toxicities with HRCT chest findings described in literature. Suh et al also described two out of 81 patients developing pneumonitis on treatment, however, detailed radiological and pathological descriptions are not available for these cases.¹¹

The median time between initiation of Dasatinib treatment and development of pulmonary toxicity noted in literature ranged from 20 to 730 days.^{1,12} Toxicity appears at doses of 100 mg or higher, suggestive of dose-related toxicity. A dose of 100 mg/d, as administered in this case, is consistent with that described in the literature.^{2,3,7,8} Most pulmonary toxicities resolve completely on halting the drug and treatment with steroids, like this case, suggesting an immune reaction. Reintroduction of drugs at a low dose after the complete resolution has led to mixed results.⁸

Our patient had left lower lobe interlobular septal thickening suggestive of ILD confirmed on lung function testing, imaging, and histopathology. The interstitial infiltrate was predominantly lymphocytic, much like the effusion. The recognition of drug-induced diffuse lung disease is always challenging in lung pathology because most of the histopathologic changes identified are nonspecific as noticed in this case and simulate those seen with other causes of diffuse lung disease. Hence, the diagnosis of a drug-mediated diffuse lung disease requires careful exclusion of other causes. The histopathological features related to Dasatinib toxicity were rarely described previously.^{4,13}

Further, the absence of infection and collagen vascular disease markers, low ADA with normal cardiac functions, abatement of symptoms on cessation of the Dasatinib treatment and brisk response to corticosteroids, substantiate Dasatinib-induced pleuropulmonary toxicity. The interval between the initiation of Dasatinib and the reported side effect in our patient was much longer at 982 days than described previously. While there was a marked improvement in FVC with normalization of functions, the DLCO, however, remained low. The persistent low DLCO is likely due to the significant underlying smoking-related emphysema in the patient.

Approach to chemotherapy-related lung infiltrates consists of grading the toxicity after ruling out causes like infection with a bronchoalveolar lavage with or without a lung biopsy, as indicated, followed either by withholding the causative drug, or treatment with steroids, depending on the severity grading of the lung toxicity by CTCAE (Common Terminology Criteria for Adverse Events) criteria.¹⁴

Our patient had CTCAE Grade 3 lung toxicity which necessitates treatment with oral steroids rather than just

observation or cessation of the drug. The strength of our case is the presence of imaging pre and post therapy showing response along with a biopsy confirmation of the pathology.

The limitation is the lack of a bronchoalveolar lavage, as he refused a bronchoscopy with lavage and transbronchial biopsy for diagnosis fearing the risks and opted for an image-guided biopsy instead. However, his blood investigations were not in favor of infection.

Any pleural effusion which develops in an immunosuppressed patient either on or post chemotherapy needs to be evaluated with a pleural biopsy, wherever indicated, to rule out other causes like tuberculosis (TB), especially in a TB endemic country, before considering it to be related to cancer therapy.

The patient developed bilateral pleuro-pulmonary toxicity due to Dasatinib. On the right side he developed toxicity in the form of a pleural effusion whereas on the left side he developed toxicity in the form of a NSIP pattern of ILD.

The effusion was exudative with a low ADA which was not in favor of TB. Hence, we did not do a pleural biopsy and decided to treat him as a CTCAE Grade 3 Dasatinib-related lung toxicity and Dasatinib-related pleural effusion, with steroids rather than observation. He showed excellent symptomatic and radiological response with complete resolution of the effusion and the ILD to steroids and Dasatinib cessation, confirming the diagnosis which was also confirmed on the lung biopsy.

In the field of respiratory therapeutics, another TKI, Nintedanib, is recommended as an antifibrotic and anti-inflammatory agent to slow the progression of idiopathic pulmonary fibrosis.¹⁵ Clinicians need to be aware of this paradox where some TKIs can cause ILD while others are used for the treatment of ILD.

Conclusion

The clinician needs to be aware of the spectrum of pleuropulmonary toxicities of Dasatinib. Different toxicities may occur in contralateral hemithoraces. Thus, clinicians should be aware that Dasatinib causes not only isolated pleural effusions, but also pulmonary parenchymal changes that may require steroid therapy. Histopathological evidence of the toxicity aids in decision making for further treatment options and must be pursued as far as possible. In a high tuberculosis prevalent country like India, the finding of lymphocytic effusion in a patient on Dasatinib should necessitate detailed evaluation to rule out infection versus toxicity. A high degree of clinical suspicion is required for early diagnosis and prevention of progression of drug-induced lung disease.

Declaration of Patient Consent

Patient consent is taken at the time of patient's registration at the Hospital for use of their anonymized data for research purpose.

Sources of Support

None.

Funding

None.

Conflict of Interest

None declared.

Acknowledgments

None.

References

- Nam S, Kim D, Cheng JQ, et al. Action of the Src family kinase inhibitor, dasatinib (BMS-354825), on human prostate cancer cells. *Cancer Res* 2005;65(20):9185–9189
- Sakoda Y, Arimori Y, Ueno M, Matsumoto T. A suspected case of an alveolar haemorrhage caused by Dasatinib. *Intern Med* 2017;56(02):203–206
- Radaelli F, Bramanti S, Fantini NN, Fabio G, Greco I, Lambertenghi-Delilieri G. Dasatinib-related alveolar pneumonia responsive to corticosteroids. *Leuk Lymphoma* 2006;47(06):1180–1181
- Jasielec JK, Larson RA. Dasatinib-related pulmonary toxicity mimicking an atypical infection. *J Clin Oncol* 2016;34(06):e46–e48
- Montani D, Bergot E, Günther S, et al. Pulmonary arterial hypertension in patients treated by Dasatinib. *Circulation* 2012;125(17):2128–2137
- Talpaz M, Shah NP, Kantarjian H, et al. Dasatinib in imatinib-resistant Philadelphia chromosome-positive leukemias. *N Engl J Med* 2006;354(24):2531–2541
- Quintás-Cardama A, Kantarjian H, O'Brien S, et al. Pleural effusion in patients with chronic myelogenous leukemia treated with Dasatinib after imatinib failure. *J Clin Oncol* 2007;25(25):3908–3914
- Bergeron A, Réa D, Levy V, et al. Lung abnormalities after Dasatinib treatment for chronic myeloid leukemia: a case series. *Am J Respir Crit Care Med* 2007;176(08):814–818
- Qiu Z-Y, Xu W, Li J-Y. Large granular lymphocytosis during Dasatinib therapy. *Cancer Biol Ther* 2014;15(03):247–255
- Nagata Y, Ohashi K, Fukuda S, Kamata N, Akiyama H, Sakamaki H. Clinical features of dasatinib-induced large granular lymphocytosis and pleural effusion. *Int J Hematol* 2010;91(05):799–807
- Suh KJ, Lee JY, Shin D-Y, et al. Analysis of adverse events associated with Dasatinib and nilotinib treatments in chronic-phase chronic myeloid leukemia patients outside clinical trials. *Int J Hematol* 2017;106(02):229–239
- Sato M, Watanabe S, Aoki N, et al. A case of drug-induced organizing pneumonia caused by Dasatinib. *Gan To Kagaku Ryoho* 2018;45(05):851–854
- Zitnik RJ, Matthey RA. *Drug-Induced Lung Disease*. 3rd ed. Interstitial Lung Disease. Hamilton, Ontario: Mosby Yearbook; 1998
- Common Terminology Criteria for Adverse Events (CTCAE) 2017. Available at: https://ctep.cancer.gov/protocolDevelopment/templates_applications.htm
- Flaherty KR, Wells AU, Cottin V, et al; INBUILD Trial Investigators. Nintedanib in progressive fibrosing interstitial lung diseases. *N Engl J Med* 2019;381(18):1718–1727
- Iurlo A, Galimberti S, Abruzzese E, et al. Pleural effusion and molecular response in Dasatinib-treated chronic myeloid leukemia patients in a real-life Italian multicenter series. *Ann Hematol* 2018;97(01):95–100
- Cortes JE, Saglio G, Kantarjian HM, et al. Final 5-year study results of DASISION: the Dasatinib versus imatinib study in Treatment-Naïve Chronic Myeloid Leukemia Patients Trial. *J Clin Oncol* 2016;34(20):2333–2340
- Shah NP, Rousselot P, Schiffer C, et al. Dasatinib in imatinib-resistant or -intolerant chronic-phase, chronic myeloid leukemia patients: 7-year follow-up of study CA180-034. *Am J Hematol* 2016;91(09):869–874
- Hagihara M, Iriyama N, Yoshida C, et al. Association of pleural effusion with an early molecular response in patients with newly diagnosed chronic-phase chronic myeloid leukemia receiving Dasatinib: results of a D-First study. *Oncol Rep* 2016;36(05):2976–2982
- Kantarjian H, Cortes J, Kim D-W, et al. Phase 3 study of Dasatinib 140 mg once daily versus 70 mg twice daily in patients with chronic myeloid leukemia in accelerated phase resistant or intolerant to imatinib: 15-month median follow-up. *Blood* 2009;113(25):6322–6329
- Kim D-W, Saussele S, Williams LA, et al. Outcomes of switching to Dasatinib after imatinib-related low-grade adverse events in patients with chronic myeloid leukemia in chronic phase: the DASPERSE study. *Ann Hematol* 2018;97(08):1357–1367
- Cortes J, Kim D-W, Raffoux E, et al. Efficacy and safety of Dasatinib in imatinib-resistant or -intolerant patients with chronic myeloid leukemia in blast phase. *Leukemia* 2008;22(12):2176–2183
- Apperley JF, Cortes JE, Kim D-W, et al. Dasatinib in the treatment of chronic myeloid leukemia in accelerated phase after imatinib failure: the START of a trial. *J Clin Oncol* 2009;27(21):3472–3479
- Hochhaus A, Baccarani M, Deininger M, et al. Dasatinib induces durable cytogenetic responses in patients with chronic myelogenous leukemia in chronic phase with resistance or intolerance to imatinib. *Leukemia* 2008;22(06):1200–1206
- Fox LC, Cummins KD, Costello B, et al. The incidence and natural history of Dasatinib complications in the treatment of chronic myeloid leukemia. *Blood Adv* 2017;1(13):802–811