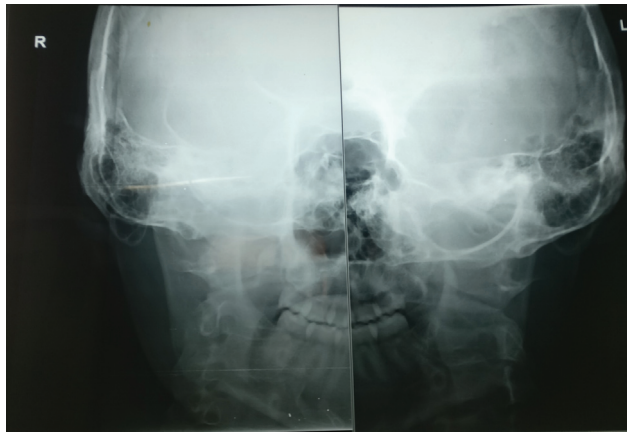
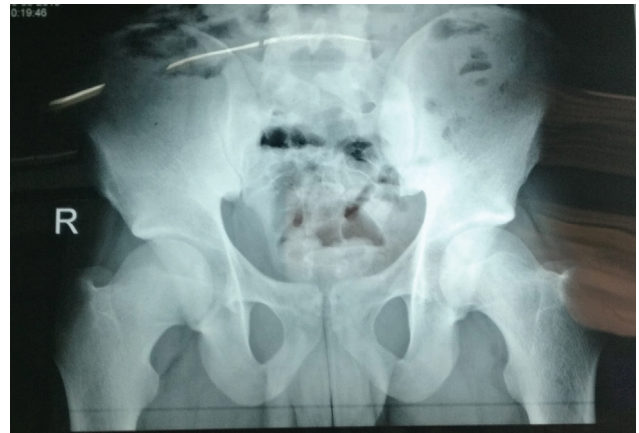
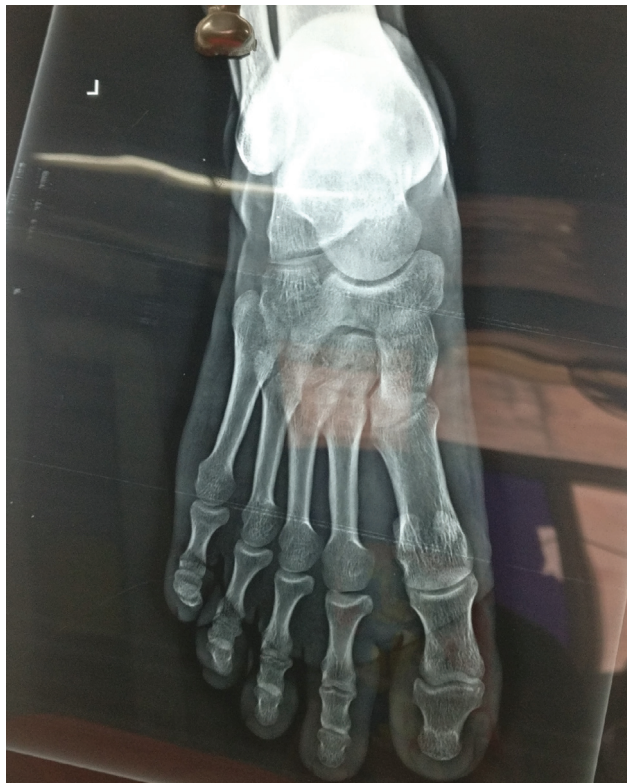

Supplementary Fig. 1 X-ray pelvis with bilateral hip joints AP view without any changes of arthritis.



Supplementary Fig. 2 X-ray left foot AP view with no significant abnormality.



Supplementary Fig. 3 RT-PCR for PML-RAR? positive for BCR1 transcript.

Supplementary File 1 X-ray bilateral temporo-mandibular joint AP view showing no significant abnormality



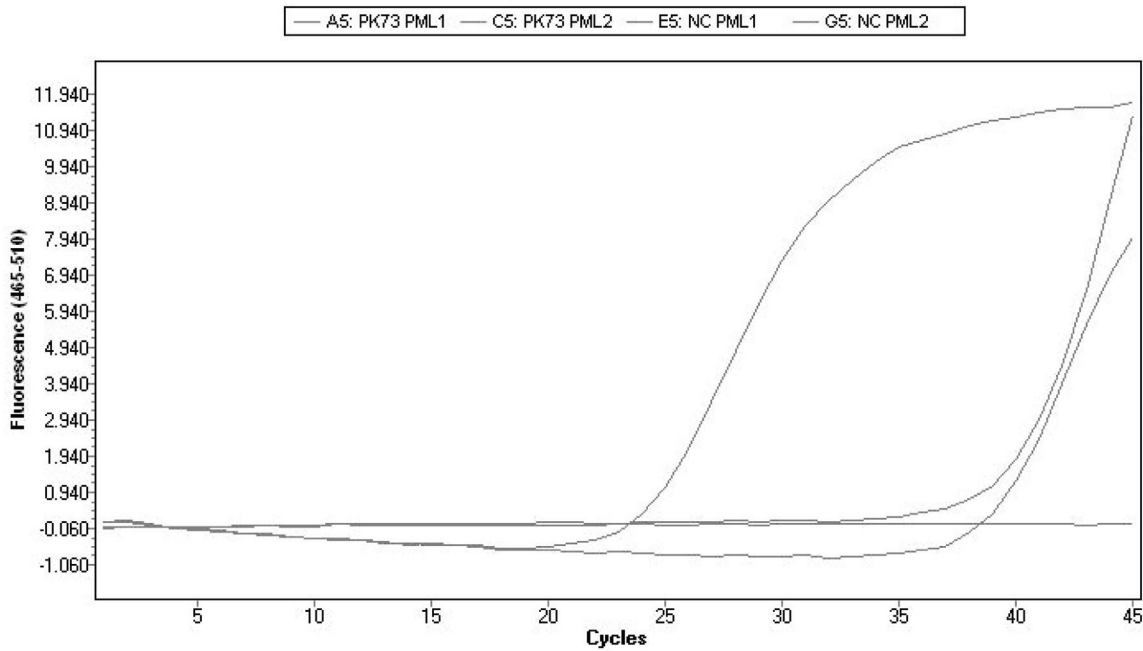
Abs Quant/2nd Derivative Max for PML-RARA (Abs Quant/2nd Derivative Max)

Results

Inc	Pos	Name	Type	CP	Concentration	Standard	Status
<input checked="" type="checkbox"/>	A5	PK73 PML1	Unknown	24.06			
<input checked="" type="checkbox"/>	C5	PK73 PML2	Unknown	39.10			
<input checked="" type="checkbox"/>	E5	NC PML1	Unknown				
<input checked="" type="checkbox"/>	G5	NC PML2	Unknown	40.00			>

> - Late Cp call (last five cycles) has higher uncertainty

Amplification Curves



Tm Calling for PML-RARA (Tm Calling)

Results

Inc	Pos	Sample Name	Peak 1				Peak 2				Status
			Tm	Area	Width	Height	Tm	Area	Width	Height	
<input checked="" type="checkbox"/>	A5	PK73 PML1	88.85	9.06	2.02	4.49					
<input checked="" type="checkbox"/>	C5	PK73 PML2									
<input checked="" type="checkbox"/>	E5	NC PML1									
<input checked="" type="checkbox"/>	G5	NC PML2									

