




# Double-Expressor Lymphoma in a Young Child—A Case Report and Review of Literature

Anjali Shaju<sup>1</sup> Latha M. Sneha<sup>2</sup> Nidarshana Pandian<sup>1</sup> Suresh Chandra<sup>3</sup> Sonam Poonam Nisar<sup>4</sup>  
Krishnakumar Subramanian<sup>5</sup> Priyathersini Nagarajan<sup>6</sup>

<sup>1</sup>Department of Pediatrics, Sri Ramachandra Institute of Higher Education and Research, Porur, Chennai, Tamil Nadu, India

<sup>2</sup>Department of Pediatric Hematology and Oncology, Sri Ramachandra Institute of Higher Education and Research, Porur, Chennai, Tamil Nadu, India

<sup>3</sup>Histopathology, Medgenome, Bangalore, Karnataka, India

<sup>4</sup>Department of Orbit, Oculoplasty, Reconstructive and Aesthetic Services, Sankara Nethralaya, Chennai, Tamil Nadu, India

<sup>5</sup>Pathology Department, Vision Research Foundation, Chennai, Tamil Nadu, India

Address for correspondence Latha M. Sneha, MD Pediatrics, MRCPCH, IAP PHO Fellowship, Professor, Department of Pediatric Hematology and Oncology, Sri Ramachandra Institute of Higher Education and Research, Porur, Chennai, Tamil Nadu 600116, India (e-mail: drmslatha@yahoo.com).

<sup>6</sup>Department of Pathology, Sri Ramachandra Institute of Higher Education and Research, Porur, Chennai, Tamil Nadu, India

Ind J Med Paediatr Oncol 2024;45:346–350.

## Abstract

Double hit lymphoma (DHL) and double-expressor lymphoma (DEL) are now considered as aggressive types of diffuse large B cell lymphoma. DHL is characterized by a dual rearrangement of MYC and B cell lymphoma 2 (BCL-2) and/or B cell lymphoma 6 (BCL-6) and DEL by overexpression of MYC and BCL-2. Both DHL and DEL have aggressive presentation and are more common in elderly population. We present a case of 1 ½ years old boy who presented with bilateral proptosis, and diagnosed as non-Hodgkin lymphoma with central nervous system involvement. Immunohistochemistry revealed high expression of MYC and BCL-2. Fluorescence in situ hybridization studies done to rule out DHL showed no translocation of C-MYC, Bcl-2, and Bcl-6 and hence were confirmed as double-expressor high-grade B cell lymphoma. Dual expression of C-MYC, Bcl-2, or Bcl-6 always needs further evaluation to rule out the more aggressive DHL subtypes.

## Keywords

- ▶ child
- ▶ proptosis
- ▶ non-Hodgkin lymphoma
- ▶ double-expressor lymphoma

## Introduction

Lymphomas with recurrent chromosomal breakpoints activating multiple oncogenes, and if MYC is one of them, are referred to as double hit lymphomas (DHL). Harboring a MYC rearrangement with a B cell lymphoma 2 (BCL-2) and/or B cell lymphoma 6 (BCL-6) rearrangement is now classified as high-grade B cell lymphoma.<sup>1</sup> Double-expressor lymphomas (DEL) and DHL are the new subsets of diffuse large B cell lymphoma (DLBCL) first described in 2016. DELs are DLBCL with increased expression of MYC and BCL-2 proteins by immunohistochemistry (IHC) but characterized by absence of detectable translocation by fluorescence in situ hybridization (FISH).

Coexpression of MYC and BCL-2 proteins without underlying rearrangements is currently considered as a new adverse prognostic indicator. DHL and DEL are distinct biological entities associated with aggressive disease, high rates of central nervous system (CNS) involvement, and very inferior clinical outcomes to standard chemotherapy regimens. This subset of lymphomas is generally seen in elderly and is rarely reported in pediatric population. We report a case of 1 ½ years old male child who presented with bilateral proptosis with extensive disease with increased expression of c-Myc and Bcl-2. FISH studies ruled out DHL and confirmed the diagnosis of double-expressor high-grade B cell Lymphoma.

article published online  
September 22, 2023

DOI <https://doi.org/10.1055/s-0043-1772233>.  
ISSN 0971-5851.

© 2023. The Author(s).

This is an open access article published by Thieme under the terms of the Creative Commons Attribution License, permitting unrestricted use, distribution, and reproduction so long as the original work is properly cited. (<https://creativecommons.org/licenses/by/4.0/>)  
Thieme Medical and Scientific Publishers Pvt. Ltd., A-12, 2nd Floor, Sector 2, Noida-201301 UP, India

Hence, FISH studies are essential to identify these from other DLBCL cases to prognosticate them and to administer intensive chemotherapy.

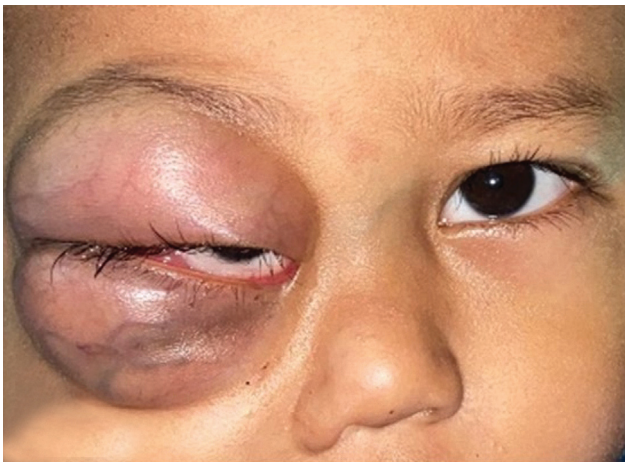## Case Report

A 1 ½ years old boy presented with complaints of progressive prominence of right eye for the past 1.5 months. There was no associated redness of eyes or discharge. The child did not have any complaints of irritability, vomiting, refusal to walk, decreased activity, fever spikes, abdominal distention, or white eye reflex prior to this episode. The parents gave a vague history of trivial trauma preceding the onset of symptoms. There was no family history of consanguinity.

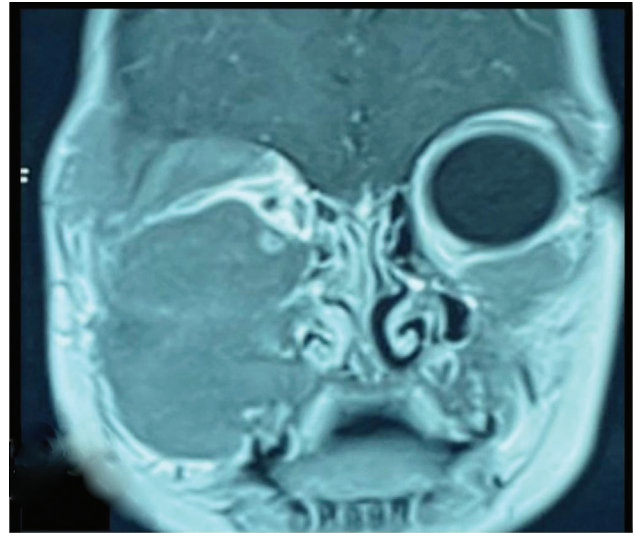
On examination, the child had a right gross ab-axial proptosis with inferomedial globe dystopia associated with fullness of the right cheek. An ill-defined, firm, noncompressible, nontender mass was palpable in the superior, lateral, and inferior quadrant (►Fig. 1). Finger insinuation test between the orbital rims or the globe was negative. Child had mechanical right eye ptosis covering the visual axis. The child resisted occlusion of the left eye for near. Extraocular movement in the right eye was restricted in all gazes and direct light reflex revealed a relative afferent pupillary defect. A visual evoked potential (VEP) test showed marked delayed P 100 latency and reduced amplitude in the right eye. Left eye was unremarkable and VEP in the left eye was within normal limits. The child was pale, but there was no lymphadenopathy or hepatosplenomegaly or mucocutaneous bleeds.

Investigations revealed a hemoglobin of 8.5 gm/dL, total counts of  $12.5 \times 10^9$  /L (polymorphs: 67%, lymphocytes: 20%; and blasts: 11%), and platelets of  $112 \times 10^9$  /L. Peripheral smear showed microcytic hypochromic anemia, white blood cells were normal in number and morphology with occasional blasts and thrombocytopenia. Renal and liver parameters were normal. Tumor lysis workup was normal.

Magnetic resonance imaging of orbit revealed a large, lobulated homogenous lesion in the right orbit, involving the superior, lateral, and inferior extra- and intraconal space



**Fig. 1** Right eccentric proptosis and periocular fullness with engorged and prominent upper lid and lower lid vessels.



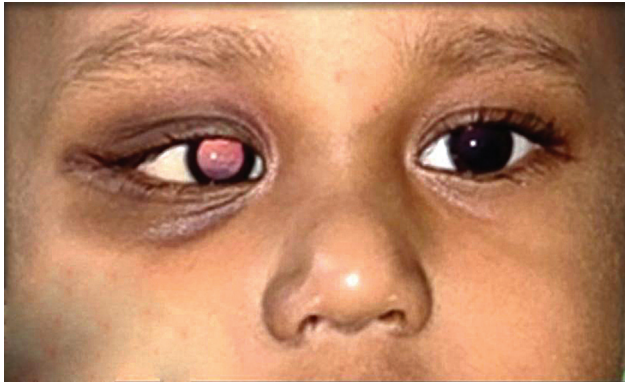**Fig. 2** Magnetic resonance imaging orbit plain, T2-weighted imaging coronal view depicting large, lobulated homogenous lesion in the right orbit, involving the superior, lateral, and inferior extra- and intraconal space extending into the pterygopalatine fossa and the cheek causing medial globe displacement. It is involving bilateral maxillary sinus causing bony erosion.

extending into the pterygopalatine fossa and the cheek causing medial globe displacement. Lateral rectus and inferior rectus could not be identified separately from the mass. The lesion displayed intermediate signal on T2-weighted imaging and was involving bilateral maxillary sinus causing bony erosion (►Fig. 2).

The child underwent an incisional biopsy of the lesion from the inferior quadrant via transconjunctival approach under general anesthesia. The rubbery, pink mass was composed of monotonous intermediate-sized round lymphoid cells with nuclear molding, prominent nucleoli, numerous mitoses with scattered tangible-body macrophages showing a starry-sky pattern. The neoplastic cells had molding with rounded and prominent nucleoli and numerous mitosis were seen.

IHC revealed CD20, CD10, CD5, CD3, Tdt, Bcl-6 negativity, and strongly positive for CD79a, Bcl-2, and C-MYC (> 95%) and Ki-67 index of more than 95%.

For metastatic evaluation of the disease, child underwent whole body positron emission tomography-computed tomography (PET-CT) and bone marrow aspiration and biopsy. PET-CT showed fluorodeoxyglucose (FDG) avid soft tissue mass (standardized uptake value [SUV]: 3.5) in bilateral orbital extraconal spaces, premaxillary, infratemporal fossa, and buccal spaces. There were permeative destruction of anterior end of bilateral zygomatic arch, lateral walls of bilateral maxillary sinuses, maxillary alveolus, and floor of orbit with aggressive sunburst type of periosteal reaction. FDG avid (SUV: 2.6) bilateral upper deep cervical lymph nodes of  $7 \times 17$  mm were noted. An extra-axial soft tissue density enhancing lesion of size  $18 \times 11$  mm was seen in the right frontal and interhemispheric falx. FDG avid epidural and paravertebral soft tissue lesions were seen in L4-S1 ( $30 \times 10$  mm; SUV: 2.4) and at S2-S4 levels ( $24 \times 6$  mm;



**Fig. 3** Complete resolution of proptosis of right eye.

SUV: 2.1). Mild diffuse increased FDG uptake was noted in distal metadiaphysis of left femur.

Bone marrow aspirate showed reactive marrow and bone marrow biopsy showed reactive marrow with trilineage hematopoiesis. In view of double-expressor status, FISH for C-MYC, BCL-2, and BCL-6 translocations was done that was normal, ruling out DHL.

Child was finally staged as group C double-expressor high-grade B cell lymphoma and was started on LMB-96 protocol and received first cycle of chemotherapy with vincristine, prednisolone, and cyclophosphamide. There was a significant reduction in the size of right eye lesion after 1 week of chemotherapy and child is currently well and on ongoing chemotherapy. At 3 months after diagnosis, the proptosis had reduced and patient had developed a left esotropia (→**Fig. 3**). Child's post-chemotherapy VEP showed improved P100 latency and amplitudes as well.

## Discussion

In view of their unique biology and clinical behavior, World Health Organization in 2016 revised the classification for lymphoma and included a new category of lymphoma called high-grade B-cell lymphoma with translocations involving Myc gene and Bcl-2 or Bcl-6 genes or cases with blastoid morphology without translocations. Lymphomas expressing MYC, BCL-2, and/ or BCL-6 at IHC level with staining threshold more than or equal to 40% for MYC and 50% for BCL-2 but not related to chromosomal rearrangement are known as double-expressor or triple-expressor lymphomas.<sup>2</sup> Those tumors that harbor a rearrangement of MYC gene and the BCL-2 or BCL-6 are called DHL and if it involves all the three, is called triple hit lymphoma (THL).<sup>3</sup>

c-MYC is a transcription factor, involved in cell growth and proliferation. The gene located on chromosome 8q24, is strictly regulated, resulting in low c-MYC protein levels and induces apoptosis by increasing the expression of P53 under normal physiological conditions. But increased expression of BCL-2 or mutation of P53 enhances the oncogenic potential of MYC. The *c-myc* gene is an oncogene, and transforms cells via unregulated overexpression of intact c-MYC protein through gene mutations, amplifications, and chromosomal translocation.<sup>4</sup> The *c-myc* gene translocation

with an immunoglobulin gene is characteristic of Burkitt lymphoma.

BCL-2 is an antiapoptotic gene and BCL-2 overexpression is synergistic with MYC, contributing to the chemoresistance and disease progression. BCL-6 is a proapoptotic gene and suppresses the activity of BCL-2 and MYC. The loss of the downregulatory effect due to mutations or translocations in BCL-6 causes lymphoma.<sup>5</sup> In the absence of chromosomal translocations, MYC and BCL-2 overexpression is attributed to gene amplification and posttranslational process.<sup>6</sup> The concurrent high expression of both MYC and BCL-2 is associated with high risk of treatment failure and the complex mechanisms of their individual contributions in terms of resistance are still unexplored.

As per Lunenburg biomarker consortium analysis, 53% of those with a MYC translocation had a rearrangement of BCL-2 and/or BCL-6 translocations, 60% of high grade B cell lymphoma had dual MYC and BCL-2 translocations, and 20% had MYC and BCL-6 translocations.<sup>7</sup> DEL accounts for 20 to 30% of DLBCL cases, whereas DHLs are present in approximately 10% of DLBCL cases.<sup>2,8</sup> Among DHLs, MYC/BCL-2 accounts for 65% and MYC/BCL-6 accounts for 14%.<sup>9</sup>

Activated B cell type is more common in DEL and germinal center B cell type is seen in DHL.<sup>10</sup> DHLs are reported to be extremely rare in younger children less than 18 years of age.<sup>11</sup> DHL and THL have a very poor prognosis due to their aggressive nature, advanced stage at presentation, and involvement of extranodal sites—bone marrow and CNS. An underlying indolent lymphoma can also transform into a DHL.<sup>12</sup> Our child too presented with extensive disease in terms of CNS involvement and extranodal location of primary tumor in the orbit.

Overexpression of MYC causing proliferative oncogenic signals and antiapoptotic survival advantage of BCL-2 overexpression results in poor outcomes with conventional chemotherapy.<sup>13</sup> DHLs have a 4 to 7% risk of CNS relapse or progression. Patients with DEL demonstrated a 10% risk of CNS relapse at 2 years.<sup>14</sup>

Unlike DH/TH lymphomas that harbor MYC and BCL-2 rearrangements, MYC and BCL-2 copy number variations do not have the high-risk gene expression. Hence, it is important to differentiate the DHLs from the larger group of DELs. DELs have better prognosis than double or THLs but have worse prognosis than the ones that does not express MYC or BCL-2 proteins. Green et al have demonstrated that patients with DEL had distinct clinical phenotype in terms of higher median age, advanced disease status with multiple extranodal sites, poor performance status, higher Ki-67 proliferative index, intermediate/high-risk International Prognostic Index (IPI) scores, and poor response to Rituximab -cyclophosphamide, doxorubicin, vincristine, prednisolone (R-CHOP) chemotherapy.<sup>15</sup>

Double-expressor status is an adverse predictive factor and Hatzl et al have quoted a 5-year survival rate of 33% for DELs.<sup>16</sup> Relapse-free survival and overall survival (OS) improved with intensive induction regimens rather than with R-CHOP.<sup>17</sup>

No difference was reported in overall, event-free survival, and complete remission (CR) rates between dose adjusted



etoposide, prednisolone, vincristine, cyclophosphamide, doxorubicin -Rituximab (DA-EPOCH-R) and R-CHOP at a median follow-up of 5 years.<sup>18</sup>

In the multicenter, study of 311 patients with DHL, Petrich et al have reported that there was no OS benefit with transplant after achieving first induction remission.<sup>19</sup>

Wu et al have reported that lymphomas with translocations involving c-MYC and BCL-2 had common immunophenotype in terms of decreased CD20 expression ranging from dim to absent.<sup>20</sup> In our case, though the translocation for MYC, BCL-2, BCL-6 was negative, IHC was negative for CD19, CD20 as seen in DH lymphomas.

All the studies quoting DELs were adult studies and to the best of our knowledge, DEL has not been reported in children less than 3 years old. In the study by Hwang et al on 41 studies of 7054 patients for double-expressor status, the youngest child reported was of 7 years of age.<sup>21</sup>

While non-Hodgkin lymphoma (NHL) is rarely diagnosed before 5 years of age, Bharatnur et al have reported NHL in a 2-year-old child and Biswas et al had reported a primary ovarian NHL in a 1-year-old patient.<sup>22,23</sup> Primary NHL of the orbital region is rare, representing 1 to 2% of all NHL and 8 to 10% of all extranodal sites. Our case is unique in terms of age of presentation and extranodal site and double-expressor status. Though our child had significant clinical response to the initial cycles of treatment, long-term follow-up is needed to assess the overall survival rate.

## Conclusion

FISH analysis for c-MYC, BCL-2, and/or BCL-6 is recommended in cases with aggressive clinical presentation, blastoid, or B cell lymphoma unclassified morphology, Germinal Center B cell (GCB) phenotype, and in cases with double expression of MYC and BCL-2 to identify the much severe DH or TH lymphoma subtypes. Novel large multicentric studies and rational targeted therapies are essential to treat this unique molecularly defined group that are very rare in pediatric age groups.

### Authors' Contributions

Latha MS conceptualized the report, performed literature review, and edited the manuscript. Anjali Shaju and Nidarshana Pandian drafted the manuscript. Krishnakumar, Suresh Chandra, Priyathersini, and Sonam Poonam edited and revised the manuscript. All authors read and approved the manuscript for publication.

### Patient's Consent

Informed consent was obtained from all individual participants included in the study.

### Funding

The authors received no financial support for the research, authorship, and/or publication of this article.

### Conflict of Interest

None declared.

## References

- Riedell PA, Smith SM. Double hit and double expressors in lymphoma: definition and treatment. *Cancer* 2018;124(24):4622–4632
- Swerdlow SH, Campo E, Pileri SA, et al. The 2016 revision of the World Health Organization classification of lymphoid neoplasms. *Blood* 2016;127(20):2375–2390
- Friedberg JW. Double-hit diffuse large B-cell lymphoma. *J Clin Oncol* 2012;30(28):3439–3443
- Nguyen L, Papenhausen P, Shao H. The role of c-MYC in B-cell lymphomas: diagnostic and molecular aspects. *Genes (Basel)* 2017;8(04):116
- Nagib RM, Ibrahim EM, El-Ashwah S. Double-expressor and triple-expressor lymphomas: are these prognostically distinct groups of diffuse large B-cell lymphoma? *Egypt J Pathol* 2019;39:239–243
- Karube K, Campo E. MYC alterations in diffuse large B-cell lymphomas. *Semin Hematol* 2015;52(02):97–106
- Rosenwald A, Bens S, Advani R, et al. Prognostic significance of MYC Rearrangement and Translocation partner in diffuse large B-cell lymphoma—a study by the Lunenburg lymphoma biomarker consortium. *J Clin Oncol* 2019;37(35):3359–3368
- Riedell PA, Smith SM. Double hit and double expressors in lymphoma: definition and treatment. *Cancer* 2018;124(24):4622–4632
- Landsburg DJ, Petrich AM, Abramson JS, et al. Impact of oncogene rearrangement patterns on outcomes in patients with double-hit non-Hodgkin lymphoma. *Cancer* 2016;122(04):559–564
- Hu S, Xu-Monette ZY, Tzankov A, et al. MYC/BCL2 protein coexpression contributes to the inferior survival of activated B-cell subtype of diffuse large B-cell lymphoma and demonstrates high-risk gene expression signatures: a report from The International DLBCL Rituximab-CHOP Consortium Program. *Blood* 2013;121(20):4021–4031, quiz 4250
- Oschlies I, Salaverria I, Mahn F, et al. Pediatric follicular lymphoma—a clinico-pathological study of a population-based series of patients treated within the non-Hodgkin's lymphoma-Berlin-Frankfurt-Munster (NHL-BFM) multicenter trials. *Haematologica* 2010;95(02):253–259
- Casulo C, Burack WR, Friedberg JW. Transformed follicular non-Hodgkin lymphoma. *Blood* 2015;125(01):40–47
- Davies A. Double-hit lymphoma: so what? *Hematol Oncol* 2019;37(Suppl 1):19–23
- Savage KJ, Slack GW, Mottok A, et al. Impact of dual expression of MYC and BCL2 by immunohistochemistry on the risk of CNS relapse in DLBCL. *Blood* 2016;127(18):2182–2188
- Green TM, Young KH, Visco C, et al. Immunohistochemical double-hit score is a strong predictor of outcome in patients with diffuse large B-cell lymphoma treated with rituximab plus cyclophosphamide, doxorubicin, vincristine, and prednisone. *J Clin Oncol* 2012;30(28):3460–3467
- Hatzl S, Posch F, Deutsch A, et al. Immunohistochemistry for c-myc and bcl-2 overexpression improves risk stratification in primary central nervous system lymphoma. *Hematol Oncol* 2020;38(03):277–283
- Landsburg DJ, Falkiewicz MK, Maly J, et al. Outcomes of patients with double-hit lymphoma who achieve first complete remission. *J Clin Oncol* 2017;35(20):2260–2267
- Bartlett NL, Wilson WH, Jung SH, et al. Dose-adjusted EPOCH-R compared with R-CHOP as frontline therapy for diffuse large B-cell lymphoma: clinical outcomes of the phase III intergroup trial alliance/CALGB 50303. *J Clin Oncol* 2019;37(21):1790–1799

- 19 Petrich AM, Gandhi M, Jovanovic B, et al. Impact of induction regimen and stem cell transplantation on outcomes in double-hit lymphoma: a multicenter retrospective analysis. *Blood* 2014;124(15):2354–2361
- 20 Wu D, Wood BL, Dorer R, Fromm JR. “Double-Hit” mature B-cell lymphomas show a common immunophenotype by flow cytometry that includes decreased CD20 expression. *Am J Clin Pathol* 2010;134(02):258–265
- 21 Hwang J, Suh C, Kim K, et al. The incidence and treatment response of double expression of MYC and BCL2 in patients with diffuse large B-cell lymphoma: a systematic review and meta-analysis. *Cancers (Basel)* 2021;13(13):3369
- 22 Bharatnur SS, Amirtham U, Premalata CS, Kumar RV. Distribution of non-Hodgkin lymphoma in children and adolescents. A study from a regional cancer centre in South India. *IOSR Journal of Dental and Medical Sciences* 2016;15(04):7–12. e-ISSN: 2279–0853
- 23 Biswas BK, Mondal R, Moulik D, Bagdi S. Primary ovarian non-Hodgkin’s lymphoma in a 1-year-old child: a rare case report. *Indian J Case Reports* 2020;6(04):166–168