



The Unusual Presentation of Bilateral Proptosis Presents a Dilemma in the Case of Juvenile Myelomonocytic Leukemia

Himanshu Gohatre¹  Deepali Ambike¹ Garima Singh Deo¹ Rajesh Kulkarni¹ Tushar Patil²

¹Department of Pediatrics, PCMC's Post Graduate Institute YCM Hospital, Pune, India

²Department of Pathology, PCMC's Post Graduate Institute YCM Hospital, Pune, India

Address for correspondence Dr. Himanshu Gohatre, Junior Resident, MD paediatrics, Department of Paediatrics, PCMC's Post Graduate Institute & Y.C.M. Hospital, Pune, Maharashtra, India (e-mail: drhimanshugohatre@gmail.com).

Ind J Med Paediatr Oncol

Abstract

Juvenile myelomonocytic leukemia (JMML) is a myelodysplastic/myeloproliferative neoplasm. It is a rare pediatric neoplasm occurring in early childhood. Herein, we present a case of JMML in a 4-year-old girl admitted for primary complaints of protrusion of eyes and fever for the past 15 days not responding to any medications. With findings of splenomegaly and peripheral blood smear showing severe leukocytosis and increased monocytoid and blast cells, a myelomonocytic series neoplasm was suspected. Abelson (Abl) tyrosine kinase gene break point cluster (Bcr) gene (*BCR-ABL1*) was found to be negative on fluorescence in situ hybridization (FISH). Taking into consider all these findings, the patient was diagnosed with JMML. Since hematopoietic stem cell transplantation (HSCT) is not offered at our hospital, the patient was referred to another medical facility for the required procedure. This case highlights that bilateral proptosis could be a primary finding in early cases of JMML and should not be missed.

Keywords

- ▶ proptosis
- ▶ juvenile myelomonocytic leukemia
- ▶ *BCR-ABL1*

Introduction

Leukemias are among the most common white cell malignancies in the children. White cell malignancies are broadly of three types: lymphoid neoplasms, myeloid neoplasms, and histiocytic neoplasms. Lymphoid leukemia is more common and has a better prognosis than most of the myeloid leukemias. The incidence of myeloid leukemia relatively increases in the adolescent age group and is associated with several chromosomal abnormalities. Lymphoid leukemias have a better prognosis and survival rates than myeloid leukemias. Increased supportive care and prolonged hospitalization are required in patients with leukemia.

Case Report

A 4-year-old girl was admitted with complaints of intermittent low-grade fever for 15 days. Following the onset of the

fever spike, the patient started developing swelling around both eyes (proptosis), which was symmetrical, insidious in onset, and progressively increasing in size, which led to protrusion of both eyes (▶**Fig. 1**). This was associated with conjunctival hemorrhage and dry eyes. Proptosis was not associated with pain or diminution of vision. Also, there was no history of significant weight loss or a history of malignancy in the family.

Physical examination revealed positive findings of cervical lymphadenopathy approximately 3 cm in size in the left jugular region and a firm spleen with grade 2 splenomegaly according to Hackett's classification. On complete blood count, total leukocyte count (TLC) was very high (215,400/ μ L), with basophilia (2.5%; normal values [n.v.]: 0–1.7%).

Peripheral blood smear (PBS; ▶**Fig. 2**) was suggestive of marked leukocytosis with increased blast cells and monocytoid cells. PBS also revealed the presence of myeloblasts (8%), promyelocytes (3%) myelocytes (20%), metamyelocytes (18%),

DOI <https://doi.org/10.1055/s-0044-1788704>.
ISSN 0971-5851.

© 2024. The Author(s).

This is an open access article published by Thieme under the terms of the Creative Commons Attribution License, permitting unrestricted use, distribution, and reproduction so long as the original work is properly cited. (<https://creativecommons.org/licenses/by/4.0/>)

Thieme Medical and Scientific Publishers Pvt. Ltd., A-12, 2nd Floor, Sector 2, Noida-201301 UP, India

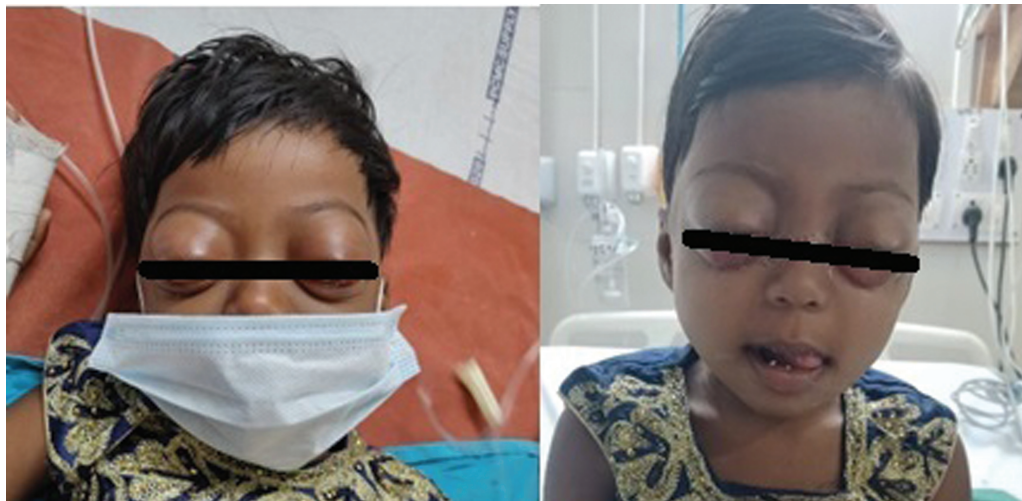

Fig. 1 Periorbital infiltrates leading to proptosis.

band cells (9%), and dysplastic monocytes (18%). Auer rods were not visible in the blasts. Additionally shown were mild thrombocytopenia and normocytic normochromic anemia.

Following a bone marrow aspirate biopsy, hypercellular marrow with a predominately myeloid series was discovered. Fifteen percent myeloblasts (n.v.: 5%), a large number of early myeloid cells, and relatively suppressed erythroid and megakaryocytic series were seen, which were suggestive of a myeloproliferative neoplasm.

Bone marrow biopsy was also done, which showed hypercellular marrow, with a myeloid series predominance and marked suppression of erythroid and megakaryocytic series. The myeloid series had progressive maturation with a prominent monocytic series. Blasts were 9% and a provisional diagnosis of JMML was made. Fluorescence in situ hybridization (FISH) for *BCR-ABL1* was negative, strongly suggesting JMML.

Thyroid function test and chest X-ray done were within normal limits. Lumbar puncture and transpalpebral biopsy were not done because the patient was not vitally stable.

Since hematopoietic stem cell transplantation (HSCT) is not offered at our hospital, the patient was referred to a higher oncology and diagnostic center for the required procedure. Standard protocol treatment was initiated and

the patient has a relatively better general condition now as per the telephonic conversation with the parents.

Discussion

JMML is an uncommon and life-threatening disorder affecting hematopoietic stem cells in infancy and early childhood. Formerly known as juvenile myelogenous leukemia, it accounts for 1% of all cases of childhood leukemia with an incidence of 1.2 cases/million with a median age of 2 years and male predominance (male-to-female ratio of 2.5).¹⁻⁵

In JMML, the differentiation pathway is directed toward monocytic differentiation, and the JMML cell's progenitor colonies exhibit a range of differentiations, encompassing blasts, monocytes, promonocytes, and macrophages.¹ Most JMML patients have mutations that activate the *RAS* oncogene pathway, like *NRAS*, *NF1*, and *PTPN11*; germline *RAS* mutations have been linked to a better prognosis than somatic *RAS* mutations. Somatic *RAS* mutations are among the common *RAS* pathway mutations in JMML.⁶⁻⁹

JMML is more common in patients with neurofibromatosis type 1 (NF-1) and Noonan's syndrome.¹⁰ Most of the patients of Noonan's syndrome with JMML have a better prognosis and a high probability of spontaneous resolution.¹¹

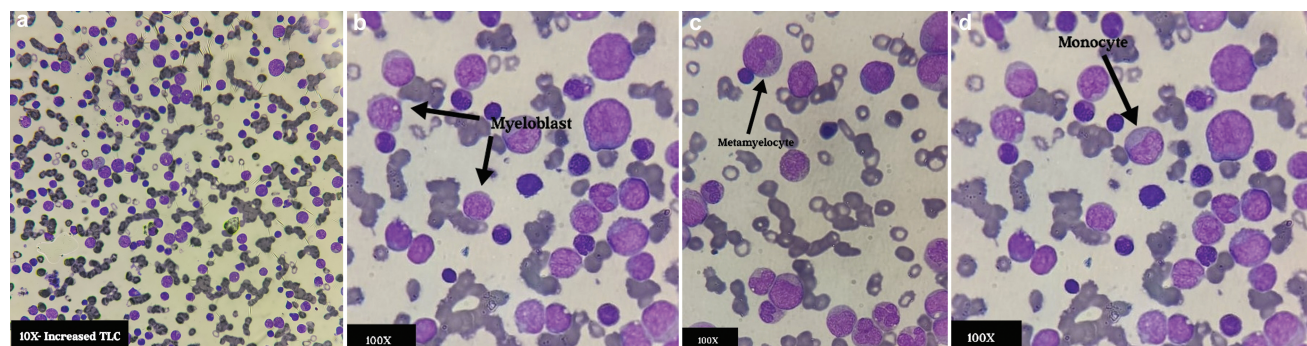


Fig. 2 The peripheral blood film (PBF) of the patient. (a) PBF showing leukocytosis with increased blast cells of all maturation stages. (b) Myeloblasts. (c, d) Metamyelocytes and monocyte suggesting monocytosis.

JMML patients may exhibit symptoms such as fever, rash, cough, pallor, infections, and lymphadenopathy. Abdominal examination usually has positive findings of splenomegaly and hepatomegaly. The presence of splenomegaly is a consistent feature in all cases and is essential for diagnosing JMML. Eczema, xanthoma, café-au-lait spots, and juvenile xanthogranuloma are a few of the skin lesions seen in these patients.¹² If the *casitas B-lineage lymphoma (CBL)* gene or *NF 1* gene germline mutations are present, then these patients can also have café-au-lait spots.¹³ Eye/orbital involvement is uncommon in JMML, with only a few such cases registered in the published literature.^{14,15} Orbital involvement is more prevalent among children, particularly those from nonindustrialized countries. Typically unilateral, it can manifest at any leukemia stage and may precede systemic disease indicators. In a series of 32 leukemic Ugandan children, orbito-ocular manifestation at the presentation constituted 18.8% of cases.¹⁶ Risk factors include lower socioeconomic status, impaired delayed hypersensitivity skin tests, diminished CD4/CD8 lymphocyte counts, and monocytic leukemia. Cases with the initial orbital disease often develop systemic leukemic features in a year of diagnosis.¹⁷ Proptosis, mainly caused by a combination of orbital muscle infiltration, leukemic infiltrates, venous blockage, and retrobulbar hemorrhage, is the predominant orbital sign in these cases.¹⁸

Respiratory distress with a cough secondary to intestinal infiltrates is usually seen when the respiratory system is involved. In others, tractable diarrhea, gastrointestinal infections with hemorrhagic manifestations are seen in patients

with gastrointestinal involvement. Central nervous system involvement is rare in JMML.³

There are multiple infections that mimic JMML, like cytomegalovirus (CMV), Epstein-Barr virus (EBV), parvovirus B19, human herpes virus 6 (HHV-6), and congenital intrauterine infections.^{19,20}

These nonmalignant infections should be ruled out in patients with high suspicion of JMML; chromosomal and/or genetic aberrations and mutation of the RAS pathway can be used to help rule out these infections.

Peripheral blood film (PBF) examination is essential in establishing the diagnosis. PBF usually shows a shift toward immaturity in the granulocytes with leukocytosis, monocytosis thrombocytopenia (which can be severe), and anemia. Absolute monocytosis of greater than 1,000/mm³ is a diagnostic criterion for the JMML. At the same time, it can be a feature of some underlying infection; thus, it is neither specific nor sensitive.

Bone marrow examination has myeloid predominance and hypercellularity. Myeloid progenitors and blasts are usually increased, but blast counts are usually less than 20% and Auer rods are not seen. They also have an abundance of monocytes (around 5–10%). In other lineages, erythroid progenitors are megaloblastic and megakaryocytes are decreased in number.²¹

JMML is diagnosed using the 2016 revision of the WHO classification as a basis for diagnosis²² (► **Table 1**).

Cytogenetics for monosomy 7, genomic sequencing for *KRAS*, *PTPN11*, *CBL*, and *NF 1* genes to find molecular alterations, and STAT-5 phosphorylation assay of *CBL* gene and

Table 1 Diagnostic criteria for JMML per the 2016 revision to WHO classification²²

JMML diagnostic criteria
I. Clinical and hematological features (all 4 features mandatory)
• PBF monocyte count $\geq 1 \times 10^9/L$
• Blast percentage in PBF and BM $<20\%$
• Splenomegaly
• Absence of Philadelphia chromosome (BCR-ABL1 rearrangement)
II. Genetic studies (1 finding sufficient)
• Somatic mutation in <i>PTPN11</i> ^a or <i>KRAS</i> ^a or <i>NRAS</i> ^a
• Clinical diagnosis of <i>NF1</i> or <i>NF1</i> mutation
• Germ line <i>CBL</i> mutation and loss of heterozygosity of <i>CBL</i> ^b
III. In addition to the clinical and hematological features mentioned under I, the following requirements must be met for patients without genetic features
• Monosomy 7 or any other chromosomal abnormality or at least 2 of the following criteria: <ul style="list-style-type: none"> – Hemoglobin F increased for age – Myeloid or erythroid precursors on PB smear – GM-CSF hypersensitivity in colony assay – Hyperphosphorylation of STAT5

Abbreviations: BM, bone marrow; CBL, casitas B-lineage lymphoma; GM-CSF, granulocyte-macrophage colony-stimulating factor; JMML; juvenile myelomonocytic leukemia; KRAS, Kirsten rat sarcoma; NF1, neurofibromin 1; NRAS, neuroblastoma rat sarcoma; PBF, peripheral blood film; PTPN11, protein tyrosine phosphatase nonreceptor type.

^aGerm line mutations (indicating Noonan syndrome) needs to be excluded.

^bOccasional cases with heterozygous splice site mutations.

high hemoglobin F levels are some of the other investigations done to support and classify diagnosed JMML.^{1,23}

The following initial factors are associated with a lower chance of survival: hepatomegaly, bleeding, thrombocytopenia, older age (>2 years), female gender, higher blast, and normoblast counts in peripheral blood.

The only definitive therapy is HSCT for most of the patients but has a greater rate of relapse of 30 to 40%.²⁴

Intensive chemotherapy by acute myeloid leukemia (AML) protocols could induce temporary remission in JMML but is very detrimental to the patient, and the European Working Group of Myelodysplastic Syndrome (EWOG-MDS) trial showed no major variation in mortality and survival rates in patients on these AML protocols as compared to less intensive treatment.²⁴ As a chemotherapeutic agent, fludarabine in high doses (30 mg/m²) has been used as a cytoreductive therapy in aggressive cases before HSCT.²⁵ Prior to this for many decades 6-mercaptopurine (50 mg/m²) or cytarabine (40 mg/m²) was used prior to HSCT, but none of these therapies have shown any improvement in the outcome of patients with JMML.²⁶

In March 2011, azacitidine had been approved for JMML therapy by the Food and Drug Administration (FDA). Following FDA approval, a study in Slovakia used azacitidine in doses of 75 mg/m² as a bridging therapy before the HSCT and observed favorable response with fewer adverse effects. Another similar study used azacitidine monotherapy in newly diagnosed cases of JMML following favorable outcomes shown in the Slovakia-based study.²⁷ In other studies, Hashmi et al have reported the disappearance of monosomy 7 clones in JMML without HSCT and sustained remission after azacitidine treatment. Therefore, the majority of patients currently receive azacitidine as standard care prior to undergoing HSCT.²⁸

Patient Consent

Declaration of the patient consent form

Written, Informed Patient Consent: Obtained

All authors have read and approved the final manuscript.

Funding

None.

Conflict of Interest

None declared.

References

- Chan RJ, Cooper T, Kratz CP, Weiss B, Loh ML. Juvenile myelomonocytic leukemia: a report from the 2nd International JMML Symposium. *Leuk Res* 2009;33(03):355–362
- Emanuel PD. Juvenile myelomonocytic leukemia. *Curr Hematol Rep* 2004;3(03):203–209
- Niemeyer CM, Arico M, Basso G, et al; European Working Group on Myelodysplastic Syndromes in Childhood (EWOG-MDS) Chronic myelomonocytic leukemia in childhood: a retrospective analysis of 110 cases. *Blood* 1997;89(10):3534–3543
- Emanuel PD. Myelodysplasia and myeloproliferative disorders in childhood: an update. *Br J Haematol* 1999;105(04):852–863
- Sasaki H, Manabe A, Kojima S, et al; MDS Committee of the Japanese Society of Pediatric Hematology, Japan. Myelodysplastic syndrome in childhood: a retrospective study of 189 patients in Japan. *Leukemia* 2001;15(11):1713–1720
- Tartaglia M, Niemeyer CM, Fragale A, et al. Somatic mutations in PTPN11 in juvenile myelomonocytic leukemia, myelodysplastic syndromes and acute myeloid leukemia. *Nat Genet* 2003;34(02):148–150
- Miyauchi J, Asada M, Sasaki M, Tsunematsu Y, Kojima S, Mizutani S. Mutations of the N-RAS gene in juvenile chronic myelogenous leukemia. *Blood* 1994;83(08):2248–2254
- Side LE, Emanuel PD, Taylor B, et al. Mutations of the NF1 gene in children with juvenile myelomonocytic leukemia without clinical evidence of neurofibromatosis, type 1. *Blood* 1998;92(01):267–272
- Flotho C, Valcamonica S, Mach-Pascual S, et al. RAS mutations and clonality analysis in children with juvenile myelomonocytic leukemia (JMML). *Leukemia* 1999;13(01):32–37
- Stiller CA, Chessells JM, Fitchett M. Neurofibromatosis and childhood leukaemia/lymphoma: a population-based UKCCSG study. *Br J Cancer* 1994;70(05):969–972
- Bader-Meunier B, Tchernia G, Miélot F, et al. Occurrence of myeloproliferative disorder in patients with Noonan syndrome. *J Pediatr* 1997;130(06):885–889
- Urs L, Stevens L, Kahwash SB. Leukemia presenting as solid tumors: report of four pediatric cases and review of the literature. *Pediatr Dev Pathol* 2008;11(05):370–376
- Niemeyer CM, Kang MW, Shin DH, et al. Germline CBL mutations cause developmental abnormalities and predispose to juvenile myelomonocytic leukemia. *Nat Genet* 2010;42(09):794–800
- Nambu M, Shimizu K, Ito S, Ohta S. A case of juvenile myelomonocytic leukemia with ocular infiltration. *Ann Hematol* 1999;78(12):568–570
- Chang GC, Moshfeghi DM, Alcorn DM. Choroidal infiltration in juvenile myelomonocytic leukaemia. *Br J Ophthalmol* 2006;90(08):1067–1067
- Davies JNP, Owor R. Chloromatous tumours in African children in Uganda. *BMJ* 1965;2(5458):405–407
- Stockl FA, Dolmetsch AM, Saornil MA, Font RL, Burnier MN Jr. Orbital granulocytic sarcoma. *Br J Ophthalmol* 1997;81(12):1084–1088
- Hmidi K, Zaouali S, Messaoud R, et al. Bilateral orbital myeloid sarcoma as initial manifestation of acute myeloid leukemia. *Int Ophthalmol* 2007;27(06):373–377
- Janik-Moszant A, Barć-Czarnecka M, van der Burg M, et al. Concomitant EBV-related B-cell proliferation and juvenile myelomonocytic leukemia in a 2-year-old child. *Leuk Res* 2008;32(01):181–184
- Lorenzana A, Lyons H, Sawaf H, Higgins M, Carrigan D, Emanuel PD. Human herpesvirus 6 infection mimicking juvenile myelomonocytic leukemia in an infant. *J Pediatr Hematol Oncol* 2002;24(02):136–141
- Emanuel PD, Bates LJ, Castleberry RP, Gualtieri RJ, Zuckerman KS. Selective hypersensitivity to granulocyte-macrophage colony-stimulating factor by juvenile chronic myeloid leukemia hematopoietic progenitors. *Blood* 1991;77(05):925–929
- Arber DA, Orazi A, Hasserjian R, et al. The 2016 revision to the World Health Organization classification of myeloid neoplasms and acute leukemia. *Blood* 2016;127(20):2391–2405
- Hasegawa D, Bugarin C, Giordan M, et al. Validation of flow cytometric phospho-STAT5 as a diagnostic tool for juvenile myelomonocytic leukemia. *Blood Cancer J* 2013;3(11):e160–e160
- Locatelli F, Nöllke P, Zecca M, et al; European Working Group on Childhood MDS European Blood and Marrow Transplantation Group. Hematopoietic stem cell transplantation (HSCT) in

- children with juvenile myelomonocytic leukemia (JMML): results of the EWOG-MDS/EBMT trial. *Blood* 2005;105(01):410–419
- 25 Niemeyer CM, Kratz C. Juvenile myelomonocytic leukemia. *Curr Oncol Rep* 2003;5(06):510–515
- 26 Bergstraesser E, Hasle H, Rogge T, et al. Non-hematopoietic stem cell transplantation treatment of juvenile myelomonocytic leukemia: a retrospective analysis and definition of response criteria. *Pediatr Blood Cancer* 2007;49(05):629–633
- 27 Fabri O, Horakova J, Bodova I, et al. Diagnosis and treatment of juvenile myelomonocytic leukemia in Slovak Republic: novel approaches. *Neoplasma* 2019;66(05):818–824
- 28 Hashmi SK, Punia JN, Marcogliese AN, et al. Sustained remission with azacitidine monotherapy and an aberrant precursor B-lymphoblast population in juvenile myelomonocytic leukemia. *Pediatr Blood Cancer* 2019;66(10):e27905