




Extraordinary Presentation of Chronic Pyelonephritis as Retroperitoneal Mass: An Image Report

Mayank Tripathi¹ Nishant Kumar¹ Kumar Vineet¹ 

¹Department of Surgical Oncology, Homi Bhabha Cancer Hospital & Mahamana Pandit Madan Mohan Malaviya Cancer Centre, Varanasi, Uttar Pradesh, India

Address for correspondence Kumar Vineet, MBBS, MS (General Surgery), Department of Surgical Oncology, Homi Bhabha Cancer Hospital & Mahamana Pandit Madan Mohan Malaviya Cancer Centre, Varanasi 221005, Uttar Pradesh, India (e-mail: likho2vineet@gmail.com).

Ind J Med Paediatr Oncol 2024;45:527–529.

Abstract

Here we are presenting a unique presentation of chronic pyelonephritis as retroperitoneal mass. It produced a diagnostic dilemma, and final diagnosis was confirmed after histopathology report.

Keywords

- ▶ retroperitoneal mass
- ▶ chronic pyelonephritis
- ▶ tumor

A 43-year-old man presented to us with the complaint of abdominal pain for 8 months and progressive increase in abdominal girth. He had no comorbidities. On examination, he had generalized abdominal pain, abdomen was distended and soft, a vague mass was palpable incorporating left hypochondrium, left lumbar, left iliac, umbilical, and hypogastrium region of abdomen. No free fluid was percussible, no renal angle tenderness was present, patient's bilateral testis were normal, and there was no generalized lymphadenopathy. Patient did not have complaint of any urinary symptoms. There was no history of fever, weight loss, or fatigue. Instead, patient gave history of gaining weight over the course of 8 months due to abdominal mass, which was not quantified. He already had an ultrasound of the whole abdomen done outside, which described a 20.6 × 25.1 cm left hypochondriac region mass extending to the lower abdomen. He had visited a local urologist with the ultrasound but could not present any documents of the same. On investigation, the patient's serum tumor markers like alpha-fetoprotein, beta-human chorionic gonadotropin, lactate dehydrogenase, blood investigations like complete blood count, kidney function test were within normal laboratory range. Urine analysis was not performed. Serum tumor markers were done as a workup for Azzopardi

tumor. Contrast-enhanced computed tomography scan of thorax–abdomen–pelvis described a large multiloculated cystic mass, which was seen arising within the retroperitoneum occupying the left half of the abdominal cavity. The mass shows multiple enhancing septations within. The mass measures approximately 23 × 14 × 28 cm. It showed few dense calcific foci within. No enhancing solid component is seen within the mass. Left kidney was not visualized.

Right kidney was unremarkable. There was no evidence of hydronephrosis. The mass was displacing the spleen cranially with elevation of left diaphragm along with displacement of the peritoneal cavity and its content to the right (→Figs. 1, 2). Since the presentation of the mass was of a retroperitoneal tumor probably arising from the left kidney, a diethylenetriamine penta-acetic acid renal scan was also performed, which showed nonfunctioning left kidney and normally functioning right kidney. After due deliberation, a decision was taken to excise the retroperitoneal mass expecting a form of sarcoma in the final histopathology report arising from kidney. Midline incision was given, and retroperitoneum was entered after mobilizing white line of Toldt. R0 resection of the mass was done along with hilar lymph nodes. Patient was discharged on postoperative day 6 and the final histopathology report came

article published online
August 27, 2024

DOI <https://doi.org/10.1055/s-0044-1789278>.
ISSN 0971-5851.

© 2024. The Author(s).

This is an open access article published by Thieme under the terms of the Creative Commons Attribution License, permitting unrestricted use, distribution, and reproduction so long as the original work is properly cited. (<https://creativecommons.org/licenses/by/4.0/>)

Thieme Medical and Scientific Publishers Pvt. Ltd., A-12, 2nd Floor, Sector 2, Noida-201301 UP, India

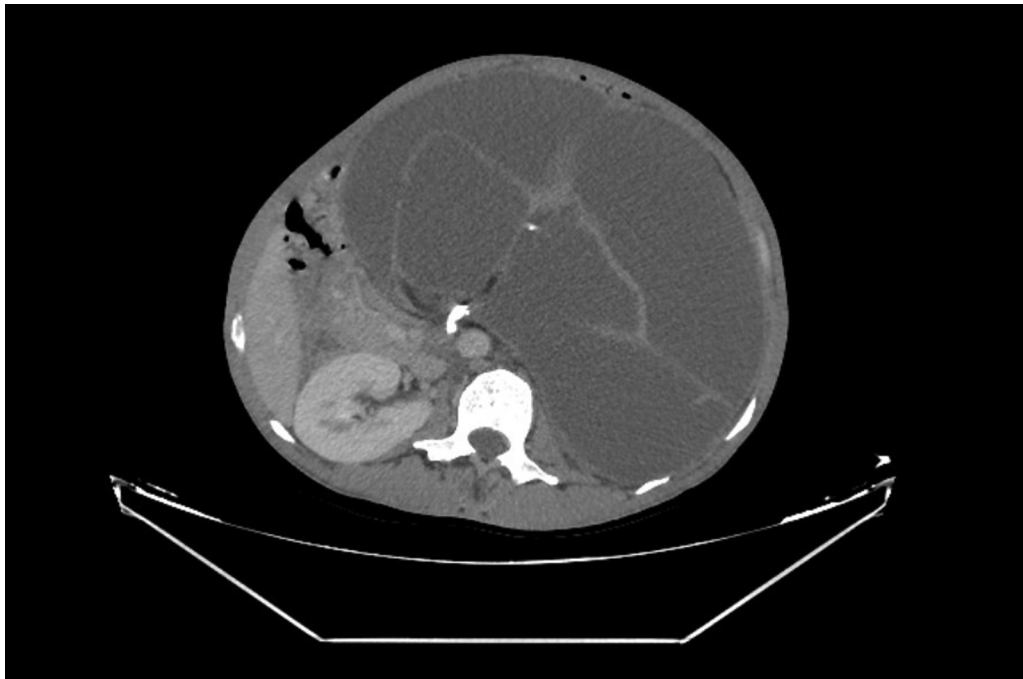


Fig. 1 Cross-sectional contrast-enhanced computed tomography at the level of right kidney is showing a cystic mass with nonenhancing septations acquiring more than half of peritoneal cavity displacing contents to right side.

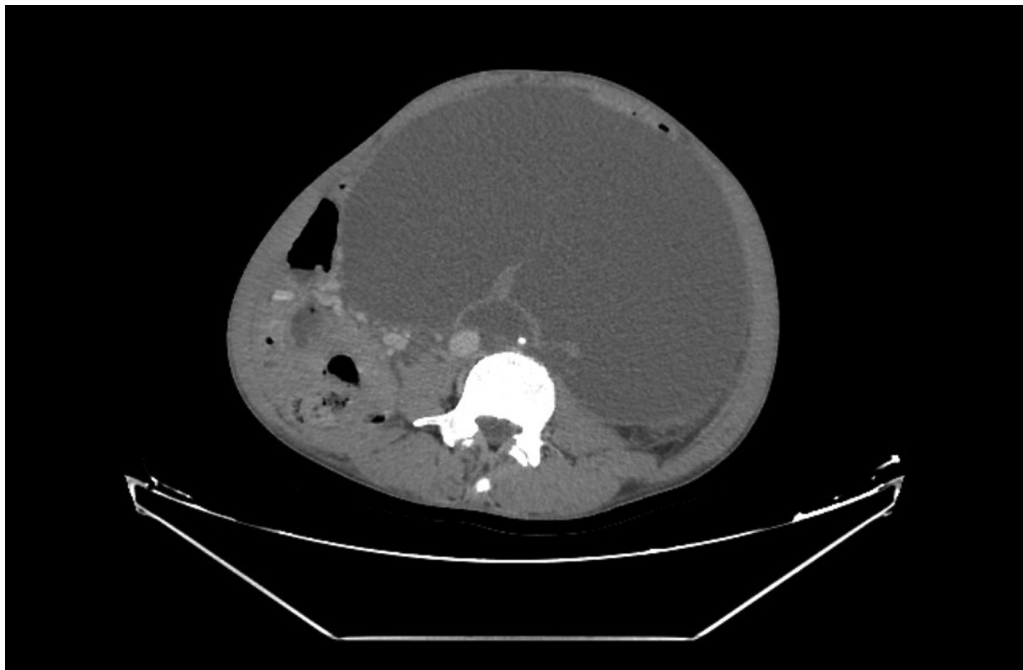


Fig. 2 Cross-sectional contrast-enhanced computed tomography below the level of right kidney is showing a cystic mass acquiring more than two third of peritoneal cavity displacing contents to right side.

out as chronic pyelonephritis described as measuring $29 \times 15 \times 10$ cm comprising kidney (measures $7 \times 4 \times 4$ cm) and ureter (measures 4.5×0.2 cm) along with multilocular cysts lesion measuring 29×15 cm. On our search, chronic pyelonephritis

presenting as a retroperitoneal mass was not found in any English medical literature. Chronic pyelonephritis mostly present as proteinuria, hypertension, and hematuria. Intra-operatively, kidney size of more than 10 cm is the common

presentation.¹ One of the lacunae in our workup for this case was no urine analysis test was performed. Our treatment approach for this case was on the point, but provisional diagnosis was not correct. This case shows that chronic pyelonephritis needs to be kept as differential diagnosis in cases of retroperitoneal mass if one of the kidneys is involved. It is one of the rarest case presentations of chronic pyelonephritis.

Conflict of Interest

None declared.

Reference

- 1 Ademola BL, Atanda AT, Aji SA, Abdu A. Clinical, morphologic and histological features of chronic pyelonephritis: an 8-year review. Niger Postgrad Med J 2020;27(01):37-41