Article published online: 2024-02-27

Clinical Feasibility of Artificial Intelligence-Based Autosegmentation of the Left Anterior Descending Artery in Radiotherapy for Breast Cancer

Aditi Mohan[1] Kaustav Talapatra[2] Manoj Sankhe[3] G. Kiron[2] Priyal Maniar[1] Akshat Kolekar[1] Saakshi Kushe[1] Prashant Kharote[3] Anuradha Singh[2] Keval Patel[1] Aayush Gupta[1] Devarsh Patel[1] Nikhil Bardeskar[4] Deepak Patkar[5]

[1] NMIMS University, MPSTME, Mumbai, Maharashtra, India
[2] Department of Radiation Oncology, Nanavati Max Super Speciality Hospital, Mumbai, Maharashtra, India
[3] NMIMS University, MPSTME, Mumbai, Maharashtra, India
[4] Nanavati Max Institute of Cancer Care, Nanavati Max Super Speciality Hospital, Mumbai, Maharashtra, India
[5] Department of Medical Service and Head Imaging Nanavati Max Super Speciality Hospital, Mumbai, Maharashtra, India

Address for correspondence Kaustav Talapatra, MD, Department of Radiation Oncology Nanavati Max Super Speciality Hospital, Mumbai, Maharashtra, India (e-mail: kaustee@gmail.com).

Ind J Med Paediatr Oncol 2026;47:274–283.

Abstract

Introduction Breast cancer is a prevalent global disease, and radiotherapy plays a crucial role in its treatment. However, radiotherapy may lead to cardiac complications, particularly in patients receiving left-sided radiotherapy who may experience increased risks due to toxicity in the left anterior descending (LAD) artery. The manual contouring of the LAD artery is time-consuming and subject to variability. This study aimed to provide an overview of artificial intelligence (AI) based LAD artery contouring, assess its feasibility, and identify its limitations.

Objectives The primary objectives were to evaluate the feasibility of AI-based LAD artery contouring, compare different approaches, and quantify properties impacting accuracy. The secondary objective was to recommend algorithms with greater accuracy.

Materials and Methods A (noncontrast) computed tomography dataset of nine patients with breast cancer was used to analyze the features and behavior of the LAD artery. The functioning of different AI models used for autosegmentation was studied, and the LAD artery imaging features were identified and quantified using the widely used AI models. Additionally, an algorithm to reliably compute interpatient variability in the LAD artery contours was proposed.

Results A lack of distinctive features, diminutive contour size (~5 pixels on average), and inconsistent position of the LAD artery were observed. The interpatient variability in the LAD artery contours was five to seven times the average size of the contours. The dataset also had a high standard deviation of 28.9 and skewed data distribution.

Conclusions The results indicated that the variable path of the LAD artery and high interpatient variability were the primary reasons for the inability of AI algorithms to

Keywords
- breast cancer radiotherapy
- autosegmentation
- left anterior descending artery contouring
- left anterior descending artery sparing
- clinical feasibility
- artificial intelligence–based contouring

article published online
February 27, 2024

DOI https://doi.org/10.1055/s-0044-1780510.
ISSN 0971-5851.

© 2024. The Author(s).
This is an open access article published by Thieme under the terms of the Creative Commons Attribution License, permitting unrestricted use, distribution, and reproduction so long as the original work is properly cited. (https://creativecommons.org/licenses/by/4.0/)
Thieme Medical and Scientific Publishers Private Limited, A-13A, Graphix Tower 1, 6th floor, Sector 62, Noida 201309, Uttar Pradesh, India

have a concordance. Further, the small contour size amplified model inaccuracy. For higher autosegmentation accuracy, an anatomical landmark–based approach is necessary to capture surrounding structures that affect the path of the LAD artery.

Introduction

In 2020, 2.3 million women were diagnosed with breast cancer and 685,000 deaths occurred globally. Moreover, 7.8 million women are living with breast cancer who were diagnosed in the past 5 years, making it the most prevalent cancer in the world.[1] Radiotherapy has demonstrated strong clinical benefits in patients treated with breast-conserving surgery or radical mastectomy. However, radiotherapy has also led to an absolute risk increase of 76.4 coronary heart disease and 125.5 cardiac deaths per 100,000 person-years.[2] Modern radiotherapy planning is a complex process that relies on computed tomography (CT) based three-dimensional imaging as well as an expert team. Based on CT simulations, radiation oncologists contour the relevant target volumes and surrounding normal structures and communicate with the dosimetrist the anticipated dosimetric goals that will deliver a therapeutic radiation dose to the target while sparing the organs at risk (OAR).

The left anterior descending (LAD) artery, a branch of the left main coronary artery, is a critical structure that supplies blood to the heart. Precise contouring of the LAD artery is essential to avoid any damage to it during radiotherapy. Patients who receive left-sided radiotherapy, compared with those receiving right-sided radiotherapy, experience increased risks of developing coronary heart disease (relative risk [RR], 1.29), cardiac death (RR, 1.22), and death from any cause (RR, 1.05).[2] Thus, cardiac toxicity is an important sequela of breast radiotherapy.[3]

Traditional manual contouring methods can be time-consuming and subject to inter- and intra-observer variability.[4] Artificial intelligence (AI) based LAD artery contouring is a method that uses AI to contour the LAD artery during radiotherapy treatment for left-sided breast cancer. AI-based contouring can be performed using machine learning (ML) algorithms and image processing techniques to analyze CT, magnetic resonance imaging (MRI), and other forms of images.[4] This can improve the accuracy of the radiation therapy and reduce the risk of damage to the surrounding healthy tissue. Research has shown that in addition to clinical benefits, automated methods can help reduce manual labor. A study on the clinical feasibility of deep learning–based autosegmentation in patients with breast cancer performed a qualitative assessment to gauge how autosegmentation would assist experts and nonexperts in real-world clinical practice. The median score on a scale of 0 to 10 for OAR for both experts and nonexperts was 9,[5] suggesting that automated contouring reduces clinical workload.

Several models have been frequently used for the AI contouring of OAR and assessing clinical target volumes (CTVs). Convolutional neural networks (CNN) with a U-Net architecture[6] have been shown to have a dice similarity coefficient (DSC) of greater than 0.80 on average while segmenting organs such as the heart, lungs, esophagus, and spinal cord.[5] Autosegmentation software Workflow Box, Embrace*CT*, and DLC*Expert* offer a DSC of 0.95 for the whole heart and 0.80 for the four cardiac chambers[7]; 0.96 for the heart, 0.98 for the lungs, and 0.82 for the spinal cord[8]; and 0.96 for the heart, 0.98 for the lungs, and 0.86 for the spinal cord,[8] respectively. However, such approaches have failed to contour structures similar to the LAD artery, such as the coronary artery.[7] Indeed, several factors, including the small volumes, tortuous motion of the LAD artery, and blurred or nonvisible LAD artery during CT due to respiratory and cardiac motion make the task of AI-based autosegmentation challenging. Thus, this study aimed to present an overview of the current state of AI-based LAD artery contouring models for the radiotherapy of left breast cancer, evaluate their feasibility, and highlight their limitations.

Methodology

Software Used

The Google Collaboratory platform, a cloud-based data analysis and ML platform, was used to perform all the analysis. The following tools and packages were used. Pydicom, a powerful python tool for handling digital imaging and communications in medicine (DICOM) files, was used for reading, editing, and writing medical imaging data, metadata manipulation, pixel processing, and for performing other advanced DICOM features.[9] Dicom_contour, a python module that works alongside the pydicom package, was used to process the contour file associated with the DICOM files of CT images.[10] Cv2 and skimage, popular image processing packages, were used for image enhancement, feature extraction, segmentation, and other processes. SciPy subpackages that specialize in the scientific fields of optimization, signal processing, and statistics were used for aiding numerical computation and data analysis. Finally, mpl_toolkits.mplot3d and ipywidgets modules, which provide advanced visualization capabilities, were used for generating three-dimensional and interactive plots for the analysis.

Approaches

In this study, two different AI-based approaches for contouring the LAD artery were identified: segmentation algorithms and atlas-based approach. Different segmentation algorithms are already widely used for various medical applications, including tumor detection and segmentation of organs,[11] and these algorithms form the base for AI algorithms mentioned earlier. In the present study, two fundamental types of segmentation

algorithms were evaluated for contouring the LAD artery: region growing and edge detection.

A multi-atlas approach creates consensus structures from a representative set of predefined library datasets and deforms contours via a majority vote onto the incoming image using the Lucas–Kanade optical flow algorithm.[12] Thus, the study also attempted to identify the cause of failure of the atlas-based approach for contouring the LAD artery. Moreover, two new AI-based approaches were developed for contouring the LAD artery, including the extrapolation-based and anatomical landmark–based approaches.

The LAD artery was extrapolated using segmentation algorithms to detect the structure near the apex of the heart where the contours were larger. The larger contours were used to project the subsequent image, thereby predicting the path of the LAD artery. In conjunction with the CT data, the anatomical landmark–based approach utilizes the delineations of several anatomical structures, such as the whole heart, left ventricle, right ventricle, left atrium, right atrium, and vessels of the heart (ascending aorta, pulmonary artery, superior vena cava, inferior vena cava, and coronary sinus), as input features for a deep learning model. The whole heart, left ventricle, right ventricle, left atrium, and right atrium contours help position the LAD artery roughly and the vessel contours help capture the randomness in the movement of the LAD artery.

Primary and Secondary Outcomes

The primary outcomes of the study were to evaluate the feasibility of defining the LAD artery region using AI, compare the feasibility of different AI-based approaches to automatically contour the LAD artery, and quantify the properties of the LAD artery impacting the accuracy of AI models. The secondary outcome was to recommend algorithms to contour the LAD artery with greater accuracy.

Inclusion and Exclusion Criteria

The inclusion criterion was women with left-sided breast cancer who underwent CT from the neck to abdomen. Women without CT data were excluded from the study.

Data Collection

For the purposes of this study, primary data were collected. CT images of nine female patients diagnosed with left-sided breast cancer were used. CT was performed from the neck to mid-abdomen, ensuring that all cardiac structures, including the LAD artery, were incorporated in the scan. All scans were performed without contrast, as the purpose was to establish the feasibility of AI-based LAD artery contouring using plain (noncontrast) CT. The CT resolution was 512×512 pixels and the CT slice thickness was 0.5 cm. The LAD artery contours were converted to a high-resolution format (RS file). This was essential as the LAD artery structure is very small. This enabled the fine-shaped LAD artery to be clearly visible. Contouring was performed with the brush tool with a size of 0.4 cm. The dataset was anonymized and the patients were labeled from 1 to 9, ensuring that no patient identity was revealed.

Data Preprocessing

The CT slices were converted to images. The slices were ordered using information from the contour file and mapped to the correct contours, and slides without contours were not included in the dataset. The contour data of the region of interest (ROI) were extracted. The contour data represent the three-dimensional coordinates of the points that comprise the ROI contour. The study dataset included two contours for the LAD artery, including that for the OAR and the body; the latter contour was not included in the analysis. These contour coordinates were transformed into pixel values for visualization. The final data frame contained patient IDs (1–9), CT arrays, LAD artery contour coordinates, and transformed pixel representation of LAD artery contours. The data frame containing 1,219 observations was saved as a .csv file.

CTs are susceptible to blurring because of respiratory and cardiac motion. Therefore, a combination of image-sharpening filters and adaptive histogram equalization was used to enhance the image (►**Fig. 1**). This approach ensures that contrast enhancement is performed locally, avoiding the overamplification of noise and preserving local details, thereby providing more defined features.

Feasibility Analysis

Segmentation Algorithms

Segmentation algorithms primarily rely on many characteristics, including similarities between pixels in direct proximity to one another or identifying edges based on contrast, texture, color, and saturation variations. Different edge detection and point detection techniques were used to capture these features of the LAD artery.

Edge detection techniques are used to capture changes in pixel value that might be indicative of an edge or boundary. Sobel and Roberts edge detection filters were used; the Sobel mask captured more detail and hence was used for the analysis. Considering how the LAD artery contours on most CT slices have a small ($\sim$5 pixels wide on average) circular shape, point detection techniques were also used. Point detection filters are used to find features such as regions in the image where there is significant edge strength in two or more directions.[13] The standard point detection mask was used for analysis.

Atlas-Based Approach

A multi-atlas-based approach requires low inter-patient variability of the structure to successfully contour it. Therefore, measures were developed to capture the inter-patient variability of the LAD artery to determine the feasibility of the multi-atlas-based approach for contouring, given that it has been shown to fail on similar structures.[7]

Extrapolation of the LAD Artery

This approach relies on the path of the LAD artery being predictable. Because the LAD artery contours are minuscule, this approach tries to leverage the knowledge of the path of the LAD artery to narrow its search and make prediction on slices where the LAD artery is indistinguishable from its surroundings. To establish the feasibility of this approach,

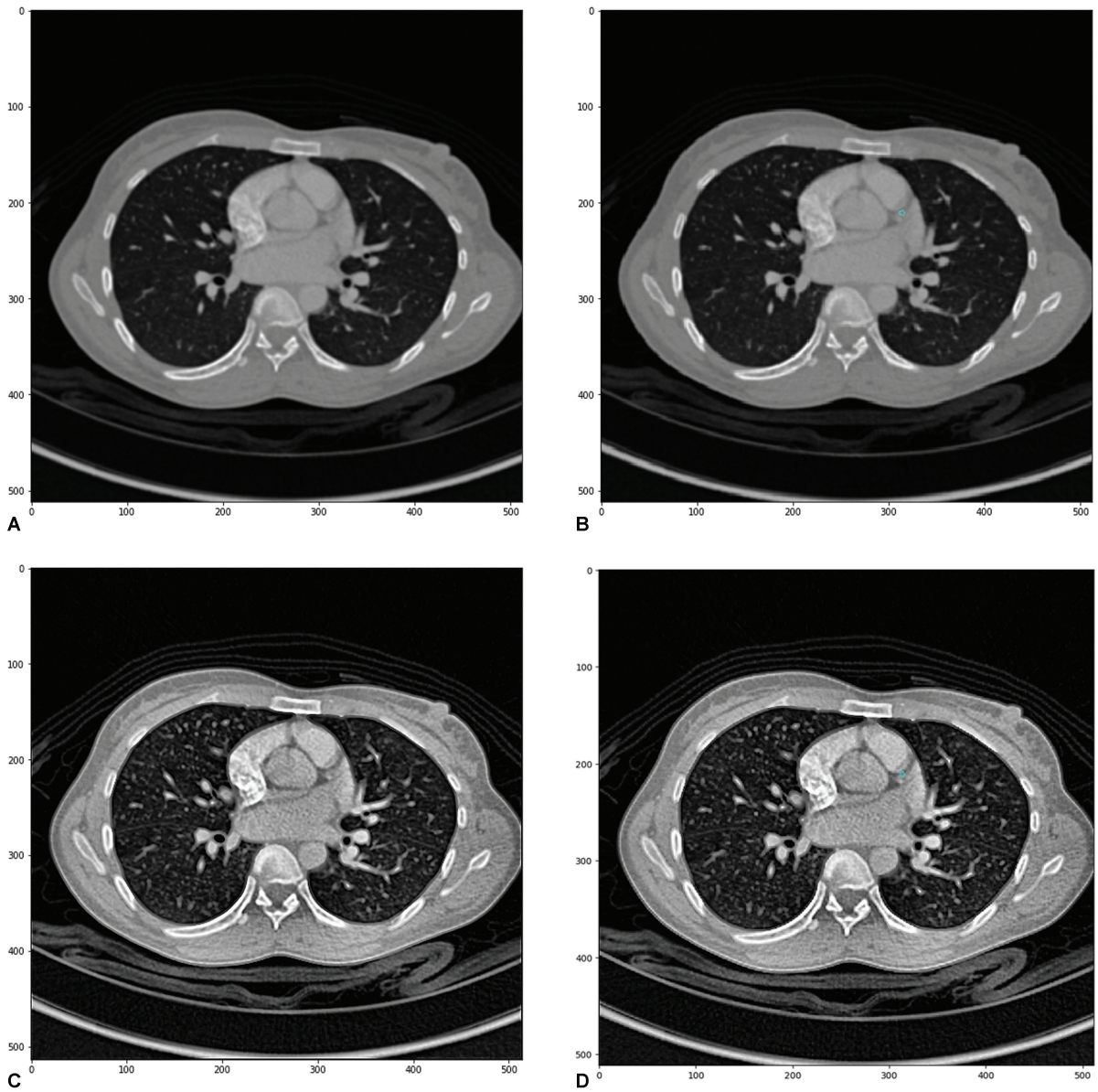

Fig. 1 Image enhancement for computed tomography (CT) scan slices. (**A**) Original CT scan slice viewed as an image. (**B**) Corresponding contour visualized on the slice. (**C**) Enhanced image of the CT scan slice. (**D**) Corresponding contour visualized on the enhanced image.

the path of the LAD artery from the apex to the base of the heart was explored.

The *x*, *y*, and *z* coordinates of the contours were normalized for an accurate analysis. The *x* and *y* coordinates denoted in millimeters (mm) were translated to pixel locations used by AI models and *z* coordinates were scaled to a range of 0 to 1 for each patient independently. This was done as the specific values of the coordinates vary based on various factors involved in the administration of CT; however, these coordinates may indicate similar pixel locations. This can distort graphical representations and cause low accuracy in AI models as they rely on the CT images and process pixel information. Thus, the center of mass (CM) of contours was also used for clear visualization.

Statistical Analysis

Several metrics were developed to capture and quantify the inter-patient variability in the LAD artery. First, mean difference (MD) in the CM of LAD artery was calculated as it expresses the average difference in the CM of the LAD artery between a pair of patients in pixels. Because the properties of the LAD artery (such as the diameter, curvature, and slope) are different for different parts of the LAD artery, merely the difference in the mean CM between patients cannot be used. Thus, to holistically capture the similarity in the path of the LAD artery between patients, the difference in the mean CM must be computed for each slice. Furthermore, different slice numbers may be available for patients. To overcome this, an algorithm was developed that compressed a large number of slices for each pair of patients to match the smaller range of slices without affecting the properties of the path of the LAD artery. The algorithm found slices closest to each other to compute the difference in the coordinates of the CM. These differences were summed and normalized with the smaller number of slices for the pair of patients. A smaller MD indicated that the positions of the LAD

artery of the two patients were more identical. Second, difference as the percentage of size of CT image was calculated. This expressed the MD defined previously as a percentage of the original size of the CT images. Thus, the MD was divided by 512 and multiplied by 100 to get the final percentage. Third, difference as the percentage of the LAD artery size was assessed. This statistic expressed the MD defined previously as a percentage of the average size of the LAD artery. Thus, the MD was divided by 5.036799 (average size of the LAD artery in pixels for the dataset) and multiplied by 100 to get the final percentage. Finally, the standard deviation (SD) of the CM was computed in a similar manner as the MD across all patients rather than pairs of patients. The total SD and MD in the CM of the LAD artery was computed as the average of the respective metric across all patients.

Ethical Approval

This study was approved by the institutional ethics committee of the hospital (approval no.: BNH/1035/2022, dated June 20, 2022), and the study was conducted in accordance with the 1964 Declaration of Helsinki and its later amendments. As hospital-based data were collected for analysis, patient consent was not required, and all patient data were anonymized.

Results

Segmentation Algorithms

The Sobel edge detection mask on the enhanced CT slices revealed no edges in the area corresponding to the contours for 98% of the slices (►**Fig. 2**). Edge detection algorithms use the difference in pixel values between the region enclosed by the edges and its surroundings to detect the edges. Thus, the absence of clear boundaries corresponding to the LAD artery contour indicated little to no distinction between the LAD artery and its surroundings toward the base of the heart, with some edges observed near the apex of the heart. Likewise, the point detection filter was unable to highlight the presence of the LAD artery in the area corresponding to the contour (►**Fig. 2**).

Atlas-Based Approach and Extrapolation of the LAD Artery

The path and behavior of the LAD artery was explored (►**Fig. 3**). It was observed that the path of the LAD artery for each patient remained erratic and unpredictable. It did not follow any pattern and was susceptible to change based on the surrounding structures, preexisting health conditions, or other unknown factors. There were substantial differences in the position of the CM of the LAD artery contours across patients (►**Fig. 3A**), indicating high inter-patient variability in the path of the LAD artery. Further, dissimilarity in the slope and curvature of the LAD artery, which are important characteristics for automated recognition, was observed. In technical terms, the slope or inclination of a line or curve is the angle it makes with the positive *x* axis and curvature is the degree to which a curve deviates from a straight line or how a curved surface deviates from a plane. The path of the LAD artery can be divided into two parts for the purpose of understanding these features. The first part is starts from the apex of the heart, followed by the small section where the LAD artery branches from the aorta. Here, the contours are wider, the curvature is gentle, and the slope is high with a small range. The second part is moving toward the bottom of the heart. In this part, the contours become narrower, the curvature increases, and the slope decreases, while its range increases.

In ►**Fig. 3C**, the *x*-axis illustrates the variation in the location of the CM of the LAD artery and the *y*-axis shows the slices of the CT. The trend of the differences in the LAD artery position, indicating the difference in the CM of the LAD artery in each slice, between all pairs of patients for each slice is shown using a line graph. An important observation was that these differences were not restricted to a particular part of the LAD artery. While comparing some pairs of patients, large differences at the start and small differences toward the end of the LAD artery were observed. However, in other cases, the exact opposite might be observed. Consequently, the reason for variability cannot be traced to a certain portion of the LAD artery being more prone to deviation while the rest of the structure remaining stable. Indeed, the entire structure is just as likely to vary.

The path of the LAD artery for all patients scaled to the original size of the CT image (512×512 pixels; ►**Fig. 3B**) appeared to form smooth and relatively straight lines. However, the zoomed plots better represented the variations in the path, as the scale was closer to the size of the contour itself. Considering the diminutive diameters (average of 5 pixels) of the LAD artery contours, variations of merely 2 to 3 pixels could lead to missing almost 50% of the LAD artery volume, giving disjointed contours and causing high inaccuracy.

The aforementioned observations were quantified using the metrics defined before. ►**Table 1** summarizes the metrics of MD in the CM of the LAD artery, difference as percentage of size of CT image, and difference as percentage of size of the LAD artery. The MD across the dataset was 30.06 pixels, which was 5.88% the size of the CT image and 596.86% the size of the LAD artery. Not much was evident by examining the MD alone, but expressing it as a percentage gave a better perspective. MD, when expressed as a percentage of the size of the LAD artery, ranged over 1,000%. Hence, the average variation in the contours was five to seven times the size of the contour itself. There was a stark contrast between the values of difference as percentage of size of the CT image and difference as percentage of size of the LAD artery, highlighting the importance of viewing the variation in the LAD artery in the right perspective. The SD of the dataset was 28.90 along the *x*-axis and 13.35 across the *y*-axis. Intuitively, the SD along the *x*-axis was higher as the LAD artery moves along it as it travels down the heart and less along the *y*-axis. In conjunction with the SD, the distribution of the dataset is visualized in ►**Fig. 4**.

Anatomical Landmark–Based Approach

A study using the whole heart, left ventricle, and right ventricle as anatomical landmarks to predict the contour of the LAD artery using IP techniques and linear regression



Fig. 2 Result of image-processing techniques to capture features of the left anterior descending (LAD) artery. (**A**) Edge detection on computed tomography (CT) scan using Sobel's mask. (**B**) Contour superimposed on the resulting image. (**C**) Point detection on CT scan. (**D**) Contour superimposed on the resulting image.

showed promising results. The DSC using this approach was only 0.15, and it could achieve a median average centroid distance of 3.9 mm and maximum Hausdorff distance of 4.8 mm.[14] This approach, however, struggled to capture the randomness in the path of the LAD artery. The approach proposed herein aims to overcome the aforementioned limitation by providing contours of the vessels of the heart as they are more clearly observed in the imaging and can help model the path of the LAD artery.

Discussion

The present study identified reasons for the inaccuracy of AI-based autosegmentation algorithms for LAD artery contouring. It examined key features of three different AI-based approaches for automatic segmentation and explored the corresponding rationales for the inability of the algorithms to have a concordance. The main observations indicated that in addition to its diminutive size, the lack of distinctive features and the meandering path of the LAD artery were the major factors for the nonperformance of these algorithms. The high inter-patient variability and SD leads to difficulty in training and evaluating these algorithms. Finally, it was observed that these metrics must be viewed with respect to the size of the contour of the LAD artery to correctly understand the impact of the variation on the performance of autosegmentation algorithms.

This study provides evidence of why segmentation algorithms commonly used for tumor detection and organ segmentation cannot be used for detecting the LAD artery. Such algorithms rely on distinctive features of the region and

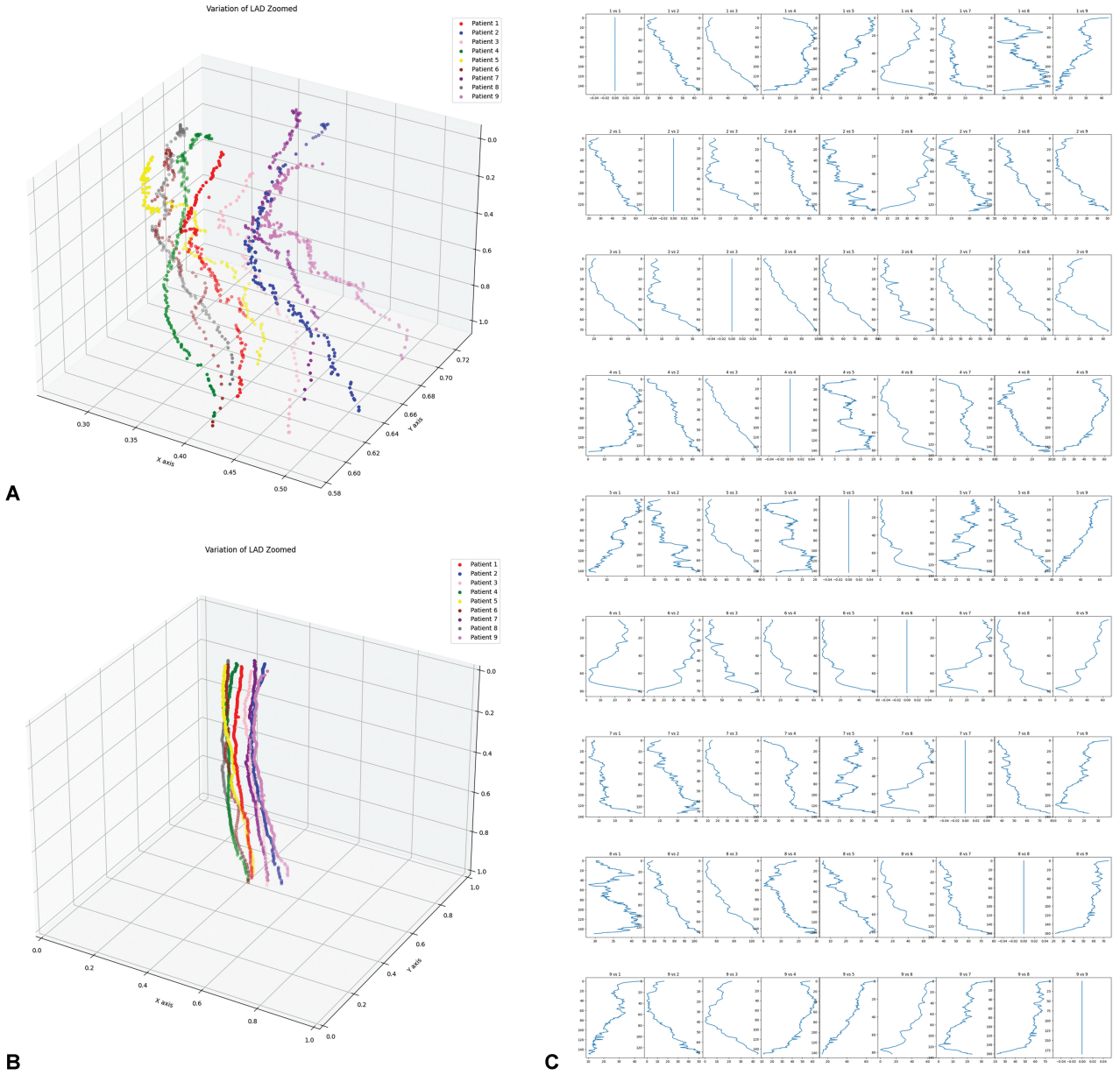

Fig. 3 Plot of the left anterior descending (LAD) artery contour centers of mass (CMs; scale: *x*-axis 0.01 = 5.11 pixels, *y*-axis 0.01 = 5.11 pixels). (**A**) Zoomed plot showcasing variability in the LAD artery path. (**B**) Plot of computed tomography (CT) scan image. (**C**) Differences between LAD artery positions in two patients.

Table 1 Summary of the metrics of MD in the CM of the LAD artery, difference as percentage of size of CT image, and difference as percentage of size of the LAD artery

	Patient 1	Patient 2	Patient 3	Patient 4	Patient 5	Patient 6	Patient 7	Patient 8	Patient 9
Mean difference in the CM of the LAD	22.797707	36.447569	36.590832	31.162679	26.795686	25.338548	24.465021	38.019966	28.945940
Difference as % of size of CT scan image	4.461391	7.132597	7.160633	6.098372	5.243774	4.958620	4.787675	7.440307	5.664567
Difference as % of size of the LAD	452.622855	723.625525	726.469866	618.699981	531.998250	503.068401	485.725512	754.843714	574.689112

Abbreviations: CM, center of mass; CT, computed tomography; LAD, left anterior descending.
Note: Each cell gives the average value for the corresponding metric across all pairs of the corresponding patient with all other patients.

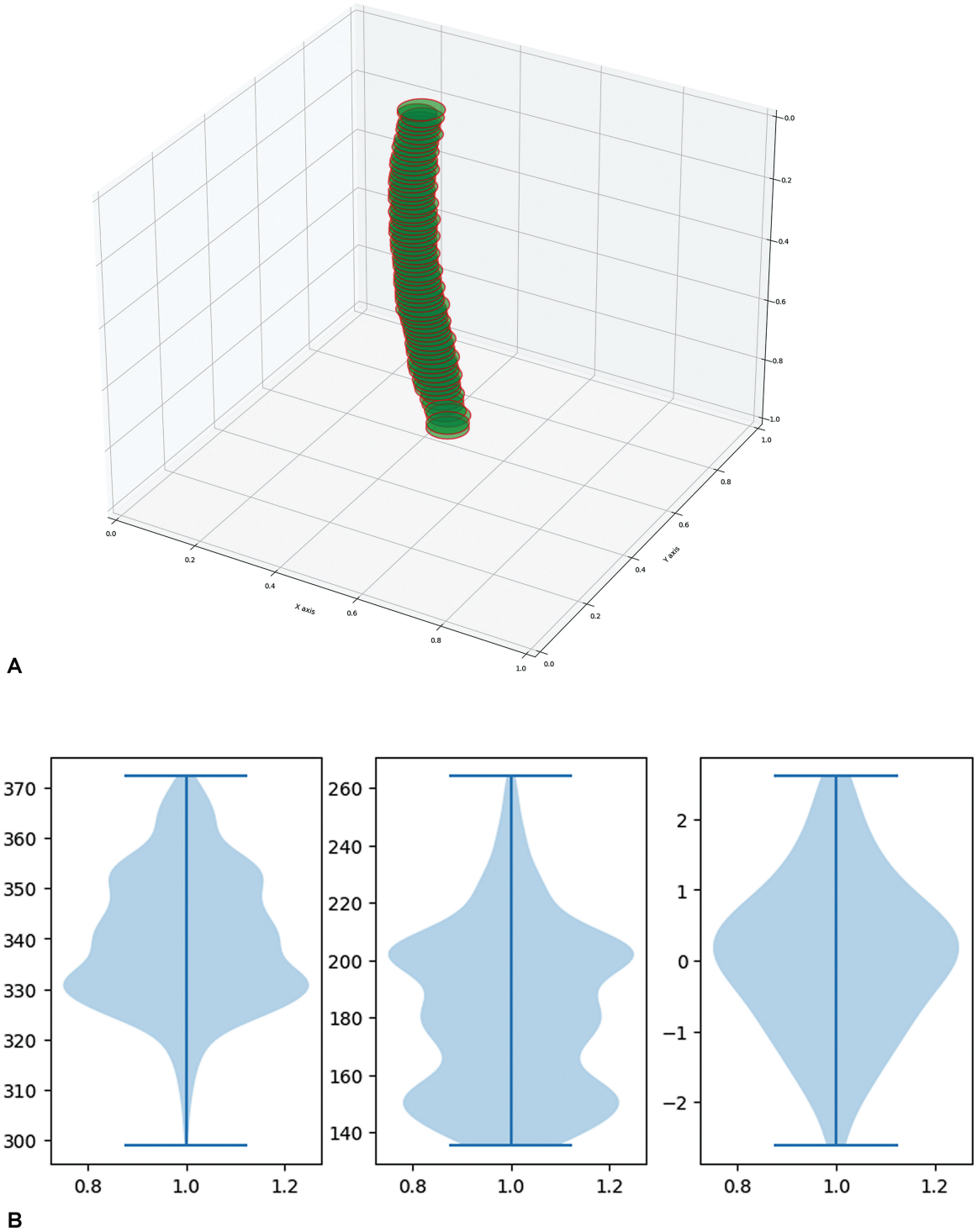

Fig. 4 Standard deviation (SD) in the left anterior descending (LAD) artery centers of mass (CMs) and distribution of the dataset. (**A**) The *green circle* represents the SD in the LAD artery centered on the mean CM of the LAD artery. (**B**) Distribution of the coordinates of the CM of the LAD artery (left and middle images, respectively); normal distribution (right image).

discernible differences between the ROI and the surrounding structures.[15] These features are absent in the LAD artery for 98% of the dataset, making such algorithms futile for LAD artery detection. The minuscule size of the LAD artery, spanning approximately 5 pixels on an average, further amplifies the error in such algorithms.

The present study results showed that the inter-patient variability of 30.06 pixels in the path of the CM of LAD artery makes the atlas-based approach for contouring the LAD artery infeasible. The high inter-patient variability also makes the extrapolation approach unlikely to succeed. Even if some of the wider contours of the LAD artery at

the apex of the heart were successfully detected, the variability in the path of the LAD artery makes it impossible to accurately project the contours toward the bottom of the heart. The SD of 28.9 in the dataset along the direction of movement of the LAD artery was too high to fit an AI model to it accurately. Thus, training on such datasets can lead to overfitting. Overfitting in ML and AI is the phenomenon where the model performs well on the training dataset but does not perform well on new data.[16] For an AI model to be deployed for use, it is important that it can generalize beyond a small set of patients on which it is trained.

There are very few existing studies on the automation of LAD artery contouring for the radiotherapy of left-sided breast cancer. A study examining the clinical feasibility of deep learning–based autosegmentation of target volumes for bilateral breasts and regional lymph nodes and OAR including the heart, lungs, esophagus, spinal cord, and thyroid in breast cancer patients after breast-conserving surgery[5] showed that the deep learning algorithm offered a DSC of 0.8 for these OAR. The difference between manual contouring and autosegmentation for OAR was small but increased as the volume of the OAR reduced. This is consistent with the findings of the current study that the accuracy of autosegmentation algorithms reduces as the target volume or OAR shrinks.

This study has several limitations. First, the number of patients considered for this study was small. Thus, a larger dataset may present more insights. Second, other imaging techniques, such as contrast CT and MRI, might provide a better visibility of the LAD artery and improve the performance of the LAD artery contouring. Finally, the manual contours used as reference were delineated by a single radiation oncologist. However, interobserver variation was not captured in the dataset.

This study can be repeated using other imaging techniques to identify the best imaging modality for LAD artery contouring. To test the proposed approach of using anatomical landmarks, this study can be replicated with the additional contours of other anatomical features to explore the correlation between the LAD artery and these features. This can further supplement the findings of this study and determine the feasibility of autosegmentation of the LAD artery using anatomical landmarks.

Conclusion

Taken together, the detection of the LAD artery is challenging because of its lack of distinctive features and 98% meandering path. The small size of the LAD artery, spanning 5 pixels, amplifies error in AI algorithms and makes extrapolation infeasible. The LAD artery, being close to the heart and a vital organ, is an important structure that requires precise contouring; incorrect contouring may lead to severe damage to the heart.[17] Therefore, owing to the complex structure and characteristics of the LAD artery, limitations of the dataset available, and limitations of existing AI-based contouring algorithms, the study results suggest that an ideal solution for LAD artery contouring is currently not feasible. Further research is needed to determine the feasibility of autosegmentation using anatomical landmarks. The successful AI-based contouring of the LAD artery can greatly impact patient outcomes. Patients receiving left-sided radiotherapy are at an increased risk of cardiac and coronary artery complications due to toxicity to the LAD artery. As manual contouring of the LAD artery is subject to variability, the use of AI for LAD artery contouring can lead to appropriate and accurate contouring. This can help provide an appropriate radiation constraint to the heart and LAD artery, thereby helping prevent cardiac and coronary artery complications.

Patient Consent
Patient consent is not required.

Conflict of interest
None declared.

References

1 World Health Organization. Breast Cancer. 2021. Accessed June 17, 2023 at: https://www.who.int/news-room/fact-sheets/detail/breast-cancer#:~:text=Scope%20of%20the%20problem,the%20world's%20 most%20prevalent%20cancer
2 Cheng YJ, Nie XY, Ji CC, et al. Long-term cardiovascular risk after radiotherapy in women with breast cancer. J Am Heart Assoc 2017;6(05):e005633
3 Feng M, Moran JM, Koelling T, et al. Development and validation of a heart atlas to study cardiac exposure to radiation following treatment for breast cancer. Int J Radiat Oncol Biol Phys 2011;79 (01):10–18
4 Marin T, Zhuo Y, Lahoud RM, et al. Deep learning-based GTV contouring modeling inter- and intra- observer variability in sarcomas. Radiother Oncol 2022;167:269–276
5 Chung SY, Chang JS, Choi MS, et al. Clinical feasibility of deep learning-based auto-segmentation of target volumes and organs-at-risk in breast cancer patients after breast-conserving surgery. Radiat Oncol 2021;16(01):44
6 Shen J, Gu P, Wang Y, Wang Z. Advances in automatic delineation of target volume and cardiac substructure in breast cancer radiotherapy (review). Oncol Lett 2023;25(03):110
7 Loap P, Tkatchenko N, Kirova Y. Evaluation of a delineation software for cardiac atlas-based autosegmentation: an example of the use of artificial intelligence in modern radiotherapy. Cancer Radiother 2020;24(08):826–833
8 Gibbons E, Hoffmann M, Westhuyzen J, Hodgson A, Chick B, Last A. Clinical evaluation of deep learning and atlas-based auto-segmentation for critical organs at risk in radiation therapy. J Med Radiat Sci 2023;70(Suppl 2):15–25
9 Pydicom. User Guide pydicom User Guide: pydicom 2.4.1 documentation. Accessed June 17, 2023 at: https://pydicom.github.io/pydicom/stable/old/pydicom_user_guide.html
10 Turgutlu K. Debut: dicom-contour. 2018. Accessed June 17, 2023 at: https://medium.com/@keremturgutlu/debut-dicom-contour-9ce74326bdbe
11 Fu Y, Lei Y, Wang T, Curran WJ, Liu T, Yang X. A review of deep learning based methods for medical image multi-organ segmentation. Phys Med 2021;85:107–122
12 Schipaanboord B, Boukerroui D, Peressutti D, et al. An evaluation of atlas selection methods for atlas-based automatic segmentation in radiotherapy treatment planning. IEEE Trans Med Imaging 2019;38 (11):2654–2664

13 University of Nevada, Reno. Corner Detection. Point Detection. Accessed June 17, 2023 at: https://www.cse.unr.edu/~bebis/CS791E/Notes/CornerDetection.pdf
14 van den Bogaard VAB, van Dijk LV, Vliegenthart R, et al. Development and evaluation of an auto-segmentation tool for the left anterior descending coronary artery of breast cancer patients based on anatomical landmarks. Radiother Oncol 2019;136:15–20
15 Kumar V, Lal T, Dhuliya P, Pant D. A study and comparison of different image segmentation algorithms. Presented at: 2016 2nd International Conference on Advances in Computing,. Communication, & Automation (ICACCA); Bareilly, India;2016:1–6
16 Paul S. Towards preventing overfitting. DataCamp. 2018. Accessed October 4, 2023 at: https://www.datacamp.com/tutorial/towards-preventing-overfitting-regularization
17 Díaz-Gavela AA, Figueiras-Graillet L, Luis ÁM, et al. Breast radiotherapy-related cardiotoxicity. when, how, why. Risk prevention and control strategies. Cancers (Basel) 2021;13(07):1712