



# First Report of a Novel Unbalanced Complex Variant Translocation t(3;9;22) with Ph Duplication and Evolving Triple Trisomy (8,12,21) in Newly Diagnosed Chronic Myeloid Leukemia without Blast Crisis: Resistance to Frontline Therapy

Suhaib Mohammad Ali Abunaser<sup>1</sup> Shruti Prem Sudha<sup>1</sup> Anurita Pais<sup>1</sup>

<sup>1</sup> Bahrain Oncology Center, Busaiteen, Kingdom of Bahrain

Ind J Med Paediatr Oncol

**Address for correspondence** Suhaib Mohammad Ali Abunaser, BMLS, Bahrain Oncology Center, Road 2835, Block 228, P.O. Box 24343, Busaiteen, Kingdom of Bahrain (e-mail: suhaib.abunaser@khuh.org.bh).

## Abstract

In chronic myeloid leukemia (CML), tyrosine kinase inhibitors (TKIs) targeting the *BCR/ABL1* fusion gene have transformed CML into a manageable condition. While most cases involve the standard t(9;22) translocation, 5 to 10% exhibit variant translocations and/or additional chromosomal abnormalities (ACAs), often linked to disease progression. Hence, cytogenetic analysis is crucial for monitoring clonal evolution and guiding treatment.

This report presents a unique case of chronic-phase CML with a three-way unbalanced variant translocation involving chromosomes 3, 9, and 22, alongside an interstitial deletion of the reciprocal *ASS1/ABL1/BCR* region. ACAs with Ph duplication and trisomy of chromosomes 8, 12, and 21 in the present case complicate the genomic landscape, with specific breakpoint involvement and additional abnormalities indicating a poorer outcome, highlighting the need for further investigation and tailored treatment strategies.

Given the rarity and poor prognostic association of this finding, our study highlights the importance of identifying complex chromosomal variations to enable modified targeted therapy regimens as first-line treatment. This emphasizes the need for individualized prognostic assessment and continuous monitoring to optimize therapeutic outcomes.

## Keywords

- chronic myeloid leukemia
- variant translocation
- karyotype
- fluorescence in situ hybridization
- imatinib
- ponatinib

## Introduction

Chronic myeloid leukemia (CML) is a hematopoietic disorder characterized by a hallmark reciprocal translocation between chromosomes 9 and 22; t(9;22)(q34;q11.2), which forms the Philadelphia (Ph) chromosome.<sup>1</sup> In over 90% of CML cases, t(9;22) is the sole abnormality; however, 5 to 10% exhibit variant Ph translocations (vPh) involving three

or more chromosomes in addition to 9 and 22. Although vPh are genetically diverse, available data suggest that patients with complex vPh do not have worse outcomes compared to those with conventional Ph-positive CML. Beyond vPh, the emergence of additional chromosomal abnormalities (ACAs) is a hallmark of clonal evolution and disease progression, particularly in CML cases progressing to blast crisis.

DOI <https://doi.org/10.1055/s-0045-1809446>.  
ISSN 0971-5851.

© 2025. The Author(s).

This is an open access article published by Thieme under the terms of the Creative Commons Attribution License, permitting unrestricted use, distribution, and reproduction so long as the original work is properly cited. (<https://creativecommons.org/licenses/by/4.0/>)

Thieme Medical and Scientific Publishers Pvt. Ltd., A-12, 2nd Floor, Sector 2, Noida-201301 UP, India

Variant Ph translocations combined with ACAs add complexity to CML, contributing to disease progression.<sup>2</sup> Consequently, cytogenetic analysis by karyotyping and fluorescence *in situ* hybridization (FISH) remains the gold standard for detecting vPh and ACAs, particularly in assessing clonal evolution, which critically impacts treatment outcomes.

To our knowledge, this is the first reported case of newly diagnosed chronic phase CML involving a variant Ph with an unbalanced atypical three-way translocation between chromosomes 3, 9, and 22, accompanied by an interstitial deletion adjacent to the translocation breakpoint on the derivative chromosome 9. Additionally, ACAs, including Ph duplication and the clonal evolution of trisomy 8, 12, and 21, were observed. This case underscores the genetic heterogeneity present in a subset of CML patients, with initial resistance to standard frontline therapies successfully overcome by third-line treatment with ponatinib, which stabilized the disease.

## Case Presentation

Our patient is a 42-year-old female patient who presented with fever and weight loss of 2 months' duration. She was admitted with COVID-19 (coronavirus disease 2019) infection and was incidentally found to have leukocytosis and hepatosplenomegaly. At presentation, her white blood cell

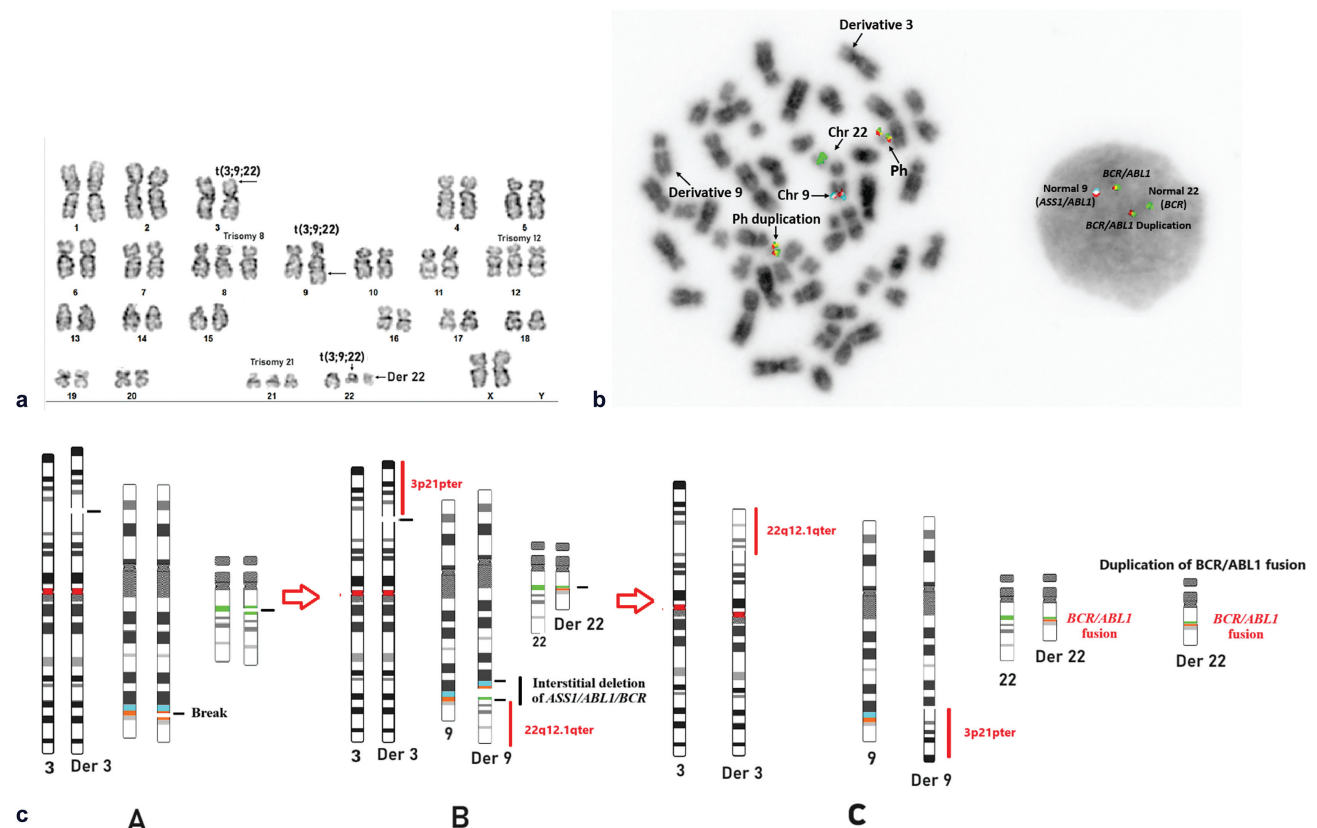
(WBC) count was  $362 \times 10^9/L$ , hemoglobin (Hb) was 64 g/L, and platelets were substantially reduced to  $17 \times 10^9/L$ . Her peripheral smear was suggestive of CML and bone marrow biopsy was consistent with chronic phase myeloid/myelomonocytic leukemia.

Bone marrow evaluation at diagnosis revealed a hypercellular marrow with considerable decreased megakaryopoiesis and erythropoiesis, accompanied by a substantial myelopoiesis with M:E ratio of 1.5:3.5 and blast percentage of 2.3%. Reticulin staining demonstrated a normal pattern (World Health Organization grade 0–1MF). Immunostaining for CD34 and CD117 identified approximately 2 to 3% scattered interstitial myeloblasts, consistent with chronic leukemia in the chronic phase (CML-CP).

## Karyotyping, FISH, and RT-PCR Analysis

The karyotype analysis at diagnosis revealed 20 metaphases with a three-way variant translocation involving chromosomes 3, 9, and 22, along with high-risk additional numerical chromosomal abnormalities, including duplication of the Ph chromosome and trisomy of chromosomes 8, 12, and 21, indicative of clonal evolution.

As per ISCN (International System for Human Cytogenomic Nomenclature) 2020 guidelines, the karyotype was described with stemline and sideline clones as sl and sd1



**Fig. 1** (a) G banded karyotype showing translocation t(3;9;22) along with duplication of Ph, trisomy of chromosome 8,12, and 21. (b) Inverted DAPI interphase and metaphase FISH showing intact *ASS1/ABL1* (aqua/orange) on normal chromosome 9, *BCR* (green) on normal chromosome 22, *BCR/ABL1* fusion (orange/green) on derivative 22 (Ph chromosome), and an additional *BCR/ABL1* fusion (orange/green) on the duplicated derivative 22 (Ph duplication). (c) Schematic illustration of the three-way complex karyotype involving chromosomes 3, 9, and 22.

designated as:

47,XX,t(3;9;22)(p21;q34;q11.2), + der(22)t(9;22)[2]/49,sl,+8,+12[16]/50,sdl1,+21[2] (►Fig. 1a).

Subsequently, FISH and metaphase chromosome analysis using LSI Dual Color Dual Fusion probes for *BCR/ABL1* (Abbott Molecular/Vysis, Des Plaines, Illinois, United States) confirmed the presence of *BCR/ABL1* fusion in all 200 interphase cells (100%), which displayed a standard 2 fusion, 1 orange, 1 green pattern. However, metaphase FISH analysis identified an unbalanced atypical variant fusion pattern, with a deletion of the reciprocal *BCR/ABL1* and *ASS1* regions on the derivative chromosome 9 with a three-way unbalanced translocation between chromosomes 3, 9, and 22 (►Fig. 1b).

Reverse transcriptase-polymerase chain reaction (RT-PCR) analysis confirmed the presence of the major (p210) *BCR/ABL1* fusion mRNA transcript.

## Treatment Course

The patient was initially started on tyrosine kinase inhibitor (TKI) therapy with imatinib. After 3 months of treatment, she exhibited labile counts due to severe thrombocytopenia and leukopenia, followed by a rapid increase in WBC counts while on imatinib.

She was subsequently switched to bosutinib, a second generation TKI, which initially yielded a good hematological response. However, after 2 months, she experienced disease progression with a WBC count increasing to  $103 \times 10^9/L$  and platelets dropping to  $15 \times 10^9/L$ . She was then treated with ponatinib, with stabilization of counts.

Due to an inadequate initial response, the patient continued to exhibit persistent leukocytosis with an increasing trend. A TKI resistance study was performed to detect *ABL1* exon 4–10 tyrosine kinase domain mutations, but no mutations were identified.

The patient had a fully human leukocyte antigen (HLA)-matched sibling donor and considering the aggressive nature of her disease, she proceeded for allogeneic bone marrow transplant. Two months post-transplant, she had evidence of decrease in donor chimerism and hematological relapse and was restarted on ponatinib and is planned for donor lymphocyte infusion (DLI).

## Discussion

Comprehensive karyotype and metaphase FISH analysis in the present case revealed multiple chromosomal breaks leading to a complex translocation. The initial break at the 9p34 and 22q11.2 regions resulted in the fusion of *BCR/ABL1* on the derivative chromosome 22. Subsequent reciprocal fusion of 22q11.2 to 9q34 occurred through two simultaneous breaks, causing an interstitial deletion involving the *ASS1/ABL1/BCR* region. The normal chromosome 9 retained the intact *ASS1/ABL1* (Aqua/Orange) which are present at spatial proximity. The region from 22q12.1 to the telomere (22qter) on the derivative chromosome 9 was replaced with

a segment from 3p21pter, as illustrated in the schematic representation (►Fig. 1c).

Our patient represents the first reported case of an unbalanced, atypical t(3;9;22) complex rearrangement. Literature on three-way complex rearrangements typically suggests a two-way mechanism for such variants. However, in the present case, the translocation appears to involve multiple complex breaks, leading to the loss of the reciprocal *BCR/ABL1* fusion segment along with *ASS1* gene on derivative chromosome 9 through a nonhomologous recombination mechanism. Under normal conditions, the reciprocal *BCR* should fuse with *ABL1* on derivative chromosome 9, but this complex rearrangement resulted in fusion followed by an interstitial deletion of the reciprocal fusion and *ASS1*. This was accompanied by a translocation of the 22q12.1qter region to 3p21 and an exchange of the 3p21pter region onto 9q34.

Metaphase FISH confirmed that the fusion signal was retained solely on the derivative chromosome 22, with the reciprocal fusion signal absent on derivative chromosome 9. Notably, two copies of the fusion signal were observed on each derivative chromosome 22, indicating Ph duplication. Clonal evolution was observed, starting with the primary stemline clone involving the t(3;9;22) translocation and Ph duplication. The second evolved clone exhibited trisomy of chromosome 8 and 12, while the third clone showed trisomy of chromosome 21. RT-PCR analysis confirmed the presence of the major (p210) *BCR/ABL1* fusion mRNA transcript.

Historical studies have indicated that vPh chromosomes with 9q deletions are associated with poor outcomes. However, in the era of imatinib, favorable outcomes have been observed regardless of the number of chromosomes involved or the presence of a 9q deletion. Nevertheless, certain cases have been linked to worse prognosis, suggesting that specific chromosomes, breakpoints, translocation complexity, and/or the presence of ACAs may influence patient outcomes. In such cases, second-generation TKIs have demonstrated improved responses. Beyond the presence of variant three-way translocations, additional major-route abnormalities such as Ph duplication, trisomy 8, and iso(17p) have prognostic importance, contributing to disease progression.

A study by Clark et al supports the notion that specific ACAs predict disease progression independently of Sokal or EUTOS long-term survival (ELTS) scores when identified at diagnosis.<sup>3</sup> Moreover, studies suggest that response to TKI therapy may be influenced by both the variant translocation mechanism and novel gene interactions resulting from chromosomal breakpoints. For instance, breakpoints in regions such as 7q22 and Xq22 have been associated with improved responses to second-generation TKIs.<sup>4–6</sup>

The coexistence of isodicentric Ph chromosomes and the three-way Ph variant t(3;9;22)(p21;q34;q11.2) has been reported as a rare finding in CML by Li Q et al. The authors suggested that *BCR/ABL1* amplification may contribute to imatinib resistance, which could be overcome by dasatinib, highlighting an alternative therapeutic strategy for CML involving isodicentric Ph chromosome.<sup>7</sup>

ACAs, such as Ph duplication leading to *BCR/ABL1* over-expression, have been associated with aggressive clinical outcomes and imatinib resistance. While trisomy 8 is often considered a secondary event following therapy, recent studies suggest that ACAs present at diagnosis increase the risk of disease progression. Notably, ACAs are not correlated with Sokal or ELTS scores, indicating their potential as independent prognostic markers for treatment decisions.<sup>8</sup>

The recurrent involvement of 3p21 in variant translocations has been documented as an apparently balanced translocation in approximately 18 cases.<sup>9</sup> Although variant translocations are not classified as a “warning” category in the imatinib era, the complexity of chromosomal abnormalities in CML remains significant due to the wide range of chromosomal involvements and specific breakpoints affecting prognosis, particularly at 3p21.

Our findings of an unbalanced three-way complex translocation, along with ACAs, highlight the importance of identifying precise breakpoints and understanding their impact on disease progression. Given the potential role of these abnormalities in influencing therapeutic response and prognosis, detailed breakpoint analysis in variant Ph translocations may provide critical insights into their genetic and pathogenic significance.

A review of the literature suggests that CML patients with t(3;9;22)(p21;q34;q11.2) tend to have an aggressive course and poor prognosis. Conversely, translocations involving the 3q region have been associated with favorable responses to imatinib, emphasizing the importance of breakpoint location as a prognostic indicator.<sup>10</sup>

The TKI resistance study in the present case showed absence of *ABL1* exon 4–10 tyrosine kinase domain mutations, suggesting that the resistance to first-line therapy in our case is likely due to the complex translocation and the presence of ACAs.

Our findings have shown that an unbalanced three-way complex translocation, along with ACAs, is associated with resistance to first-line therapy. This highlights the potential impact of complex chromosomal rearrangements on treatment response and disease progression, requiring a more tailored therapeutic approach in such cases.

Our case is the first to report t(3;9;22) as an unbalanced variant translocation with additional aneuploidies. This imbalance results from a sub-microscopic deletion on derivative chromosome 9. Large deletions in advanced-stage CML have been associated with poor prognosis, as supported by Chandran et al.<sup>11</sup>

The presence of trisomy 8, 12, and 21 in our case adds further complexity. While trisomy 8 and 21 are common in myeloid malignancies, trisomy 12 is rare, despite its involvement in recurrent translocations. Each of these trisomy has been independently linked to disease progression, genetic instability, and disruption of DNA repair mechanisms.<sup>12,13</sup>

The observed clonal evolution, with trisomy of chromosome 8, 12, and 21 arising alongside t(9;22) translocation and Ph duplication, suggests a complex genetic profile in de novo chronic-phase CML, even in the absence of blasts. Our

findings raise the possibility that an apparently balanced translocation may not only generate an oncogenic fusion but also result in the loss of tumor suppressor genes near the breakpoint. Few reports address the need for second-line treatment in complex vPh cases with ACAs. As more evidence emerges, a clearer treatment strategy is required for complex cytogenetic group. Our patient underwent a bone marrow transplant but experienced early disease progression post-transplant. Managing CML patients with complex karyotypes remain challenging necessitating careful monitoring for treatment response and disease progression. This report presents a detailed cytogenetic characterization, emphasizing the prognostic impact of complex karyotypes. A key strength of this study is its focus on early detection, modifying targeted therapy, and continuous monitoring to improve treatment outcomes. The study is based on a single case, limiting its applicability to a broader patient population. Given the poor prognosis in present case, long-term follow-up data are needed to establish definitive treatment guidelines for such cases. Further research with larger cohorts is necessary to optimize therapeutic strategies for patients with complex vPh translocations and ACAs in accordance with documented outcomes and established guidelines.

## Conclusion

Our study underscores the importance of integrating karyotyping, FISH, and molecular studies to better understand clonal dynamics in vPh cases. This is the first reported case of a patient with a complex unbalanced three-way vPh translocation and ACAs, highlighting the need for alternative therapeutic strategies. Identifying this subset of patients at high risk is essential to ensure close monitoring and timely intervention for treatment efficacy.

## Author's Contributions

S.M.A.A.: concept, design, experimental studies, data analysis, manuscript preparation, manuscript editing, and manuscript review.

S.P.S.: clinical study, data analysis, manuscript preparation, manuscript editing, and manuscript review.

A.P.: concept, literature search, data analysis, manuscript preparation, manuscript editing, and manuscript review.

## Patient Consent

## Funding

None.

## Conflict of Interest

None declared.

## Acknowledgments

We extend our gratitude to Bahrain Oncology Center for providing us with the facilities necessary to conduct this study.

## References

- 1 El-Tanani M, Nsairat H, Matalaka II, et al. The impact of the BCR-ABL oncogene in the pathology and treatment of chronic myeloid leukemia. *Pathol Res Pract* 2024;254:155161
- 2 Xue M, Cheng J, Zhao J, et al. Outcomes of 219 chronic myeloid leukaemia patients with additional chromosomal abnormalities and/or tyrosine kinase domain mutations. *Int J Lab Hematol* 2019; 41(01):94–101
- 3 Clark RE, Apperley JF, Copland M, Cicconi S. Additional chromosomal abnormalities at chronic myeloid leukemia diagnosis predict an increased risk of progression. *Blood Adv* 2021;5(04): 1102–1109
- 4 Bayrak AG, Daglar Aday A, Yavuz AS, et al. Overview of clinical and genetic features of CML patients with variant Philadelphia translocations involving chromosome 7: a case series. *Leuk Res* 2021; 111:106725
- 5 Iglesias A, Oancea R, Cotarelo C, Anguita E. Variant Philadelphia t (X;9;22)(q22;q34;q11.2) can be successfully treated with second generation tyrosine kinase inhibitors: a case report and literature review *Biomed Rep* 2021;15(04):83
- 6 Takeuchi A, Kondo T, Tasaka T, et al. Successful treatment with *ABL* tyrosine kinase inhibitor for patients with acute myeloid leukemia with *BCR-ABL1*. *Leuk Res Rep* 2020;15(15):100233
- 7 Li Q, Lin XJ, Chen H, Gong J, Li Z, Chen XN. Co-existence of isodicentric Ph chromosomes and the three-way Ph chromosome variant t(3;9;22)(p21;q34;q11) in a rare case of chronic myeloid leukemia. *Oncol Lett* 2018;15(04):4599–4603
- 8 Ansari S, Verma M. Control of Ph<sup>+</sup> and additional chromosomal abnormalities in chronic myeloid leukemia by tyrosine kinase inhibitors. *Med Oncol* 2023;40(08):237
- 9 Mitelman Database of Chromosome Aberrations and Gene Fusions in Cancer. Accessed May 22, 2025 at: <http://cgap.nci.nih.gov/Chromosomes/Mitelman>
- 10 Tan J, Cang S, Seiter K, et al. t(3;9;22) 3-way chromosome translocation in chronic myeloid leukemia is associated with poor prognosis. *Cancer Invest* 2009;27(07):718–722
- 11 Chandran RK, Geetha N, Sakthivel KM, et al. Prognostic implications of derivative chromosome 9 deletions in patients with advanced-stage chronic myelogenous leukemia. *J Environ Pathol Toxicol Oncol* 2018;37(02):117–126
- 12 Hemsing AL, Hovland R, Tsykunova G, Reikvam H. Trisomy 8 in acute myeloid leukemia. *Expert Rev Hematol* 2019;12(11): 947–958
- 13 Chen CC, Silberman RE, Ma D, et al. Inherent genome instability underlies trisomy 21-associated myeloid malignancies. *Leukemia* 2024;38(03):521–529